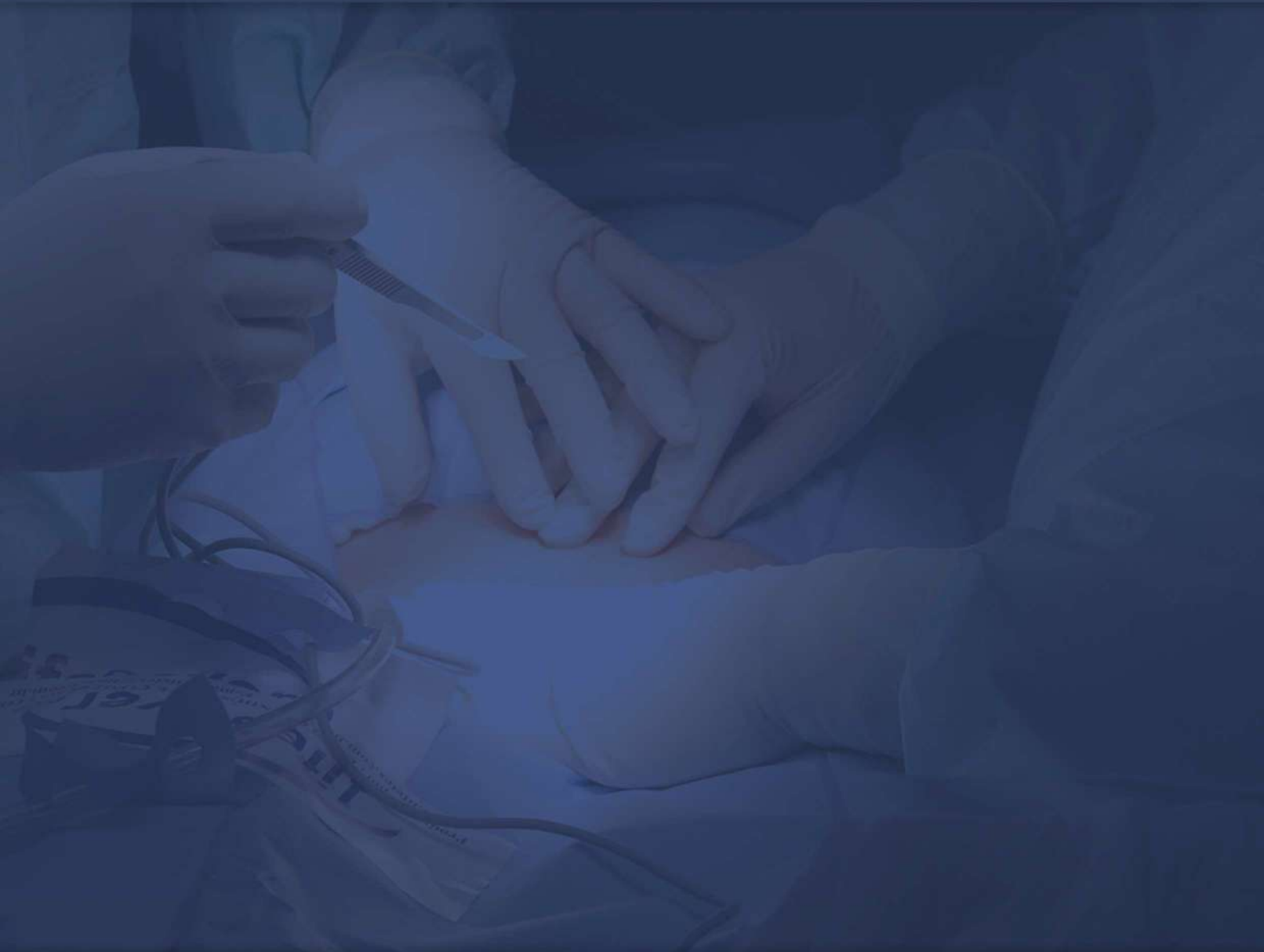

NEGATIVE PRESSURE WOUND THERAPY JOURNAL

VOLUME 8

| ISSUE 2

| AUGUST 2021



JOURNAL EDITORIAL BOARD

Editor in Chief Prof. Tomasz Banasiewicz	Poznań, Poland	Dr. Mankowski Bartosz Prof. Marciniak Ryszard Prof. Niezgoda Jeffrey A. Prof. Malinger Stanisław Prof. Oszkini Grzegorz Prof. Pramod Kumar Prof. Georgi Popivanov, Prof. Runkel Norbert Prof. Salomone Di Saverio, Prof. Sopata Maciej Prof. Szejsza Jacek Prof. Toth Csaba Dr. Trueman Paul Dr. Trzeciak Piotr Prof. Siemionow Maria Prof. Stojcev Zoran Dr. Sukhbir Singh New Prof. Szczepkowski Marek Prof. Szentkereszty Zsolt Dr. Dominik Walczak Prof. Wallner Grzegorz Prof. Wild Thomasz Prof. Veverkova Lenka Prof. Angel Zorraquino Prof. Zhou Ye-ping Dr. Zieliński Maciej	Poznań, Poland Poznań, Poland West Allis, USA Poznań, Poland Poznań, Poland Saudi Arabia Sofia, Bulgaria Villingen-Schwenningen, Germany Bologna, Italy Poznań, Poland Poznań, Poland Debrecin, Ungarn Hull, UK Belchatow, Poland Cleveland, USA Ślupsk, Poland Delhi, India Warszawa, Poland Debrecin, Ungarn Łódź, Poland Lublin, Poland Hamburg, Germany Brno, Czech Republic Bilbao, Spain Beijing, China Poznań, Poland
Statistics Editor Prof. Elżbieta Kaczmarek Managing Editor Wojciech Francuzik Editorial Board Prof. Becker Rolf Dr. Bobkiewicz Adam Dr. Borejsza Wysocki Maciej Prof. Cirocchi Roberto Dr. Cybułka Bartosz Prof. Drews Michał Prof. Duteille Franck Prof. Dżiki Adam Prof. Fracalvieri Marco Prof. Heiney Jake P. Prof. Hudson Donald Prof. Hutan Martin Prof. Ichioka Shigeru Prof. Kościński Tomasz Dr. Krokowicz Łukasz Prof. Krokowicz Piotr Prof. Larichev B. Andreia Prof. Mike G. Laukoetter	Poznań, Poland Poznań, Poland Poznań, Poland Köln, Germany Poznań, Poland Poznań, Poland Perugia, Italy Gorzów Wielkopolski, Poland Poznań, Poland Nantes, France Łódź, Poland Torino, Italy Lambertville, USA Cape Town, South Africa Bratislava, Slovakia Saitama, Japan Poznań, Poland Poznań, Poland Poznań, Poland Jaroslav Russi Muenster, Germany		

PUBLISHER

The Medigent Foundation deals with the introduction of new technologies in medicine. Mobile applications that support doctors' decisions are of particular importance to us. To date, the Foundation has completed several projects with international partners creating new solutions in the field of medicine and new technologies. We would like to invite all interested parties to cooperate: innovators, doctors and new partners, to create new tools and solutions for medicine.

Medigent - A foundation in which doctors create solutions for doctors

SUBSCRIPTIONS

Negative Pressure Wound Therapy Journal is published quarterly by Medigent Foundation in Poland.

All content is publicly available free of charge on the www.npwtj.com webpage. Readers who would like to be notified of new issues may register using a form on www.npwtj.com.

COPYRIGHT

All works published in this journal are shared under Creative Commons 4.0 Attribution Licence unless specified otherwise.

Statements and opinions expressed in the articles and communications are those of the individual contributors and not the statements and opinion of the Publisher.

DISCLAIMER

We take no responsibility or liability for any damage or injury to persons or property arising out of the use of any materials, instructions, methods or ideas contained herein. We expressly disclaim any implied warranties of merchantability or fitness for a particular purpose.

CONTACT INFORMATION

Address:

Negative Pressure Wound Therapy Journal,
Clinic of General Surgery, Gastroenterologic
Oncology and Plastic Surgery,
Przybyszewskiego 49, 60355, Poznań

Telephone: +48 61-869-12-75

Fax: +48 61-869-16-84

Electronic mail: editor@npwtj.com

Web: www.npwtj.com

Publisher:

Medigent Foundation NIP: 779 245 69 65
ul. Grunwaldzka 66/2 Poznań, 60-311 Poland
www.medigent.org

TRADEMARKS

Trademarked names appearing in the pages of NPWTJ are property of their owners. The following list should not be considered complete: V.A.C. is a trademark of Kinetic Concepts, Inc.; Pico is a trademark of Smith & Nephew.

ACKNOWLEDGEMENTS

Cover: Joanna Francuzik

SUBMISSIONS

Editors of NPWT welcome all authors to submit their works for publication in the NPWT journal. We provide a thorough peer review and best recognition of your work. Send your work to our office by logging into our website: www.npwtj.com. Please use our online form to speed up the process.

TABLE OF CONTENTS

ORIGINAL ARTICLE

MANAGEMENT OF DISTAL RADIUS FRACTURES USING CLOSED-INCISION NEGATIVE PRESSURE WOUND THERAPY.
RETROSPECTIVE STUDY.

Jakub Habr, Michal Reška, Jan Konečný, Michal Kašpar, Roman Hasara, Lenka Veverková..... 4

Management of distal radius fractures using closed-incision negative pressure wound therapy. Retrospective study.

Jakub Habr, Michal Reška, Jan Konečný, Michal Kašpar, Roman Hasara, Lenka Veverková

ORIGINAL ARTICLE

Abstract— Background: Negative pressure wound therapy has proven to be an efficient tool in the provision of temporary wound coverage in cases where definitive primary wound coverage is impossible. This initial achievement led to the use of NPWT as an incisional dressing in wounds that could be primarily closed, but posing high risk due to the amount of soft-tissue injury, location of the fracture, or high BMI.

Distal radius fracture is one of the most common injuries, especially in elderly patients. Typically, fractures occur in the osteoporotic bone as a result of low-energy trauma. Conservative treatment is still dominant in the management of distal radius fractures. In general, displaced unstable fractures or fractures that fail conservative treatment are indicated for surgical therapy. In our study, we present ten-year-experience of distal radius fracture management at our department.

Methods: Detailed analysis of retrospective data obtained from the hospital information system was carried out. The study included patients operated on at our department from January 1, 2010, to December 31, 2019. We evaluated age, gender, surgical approach, complications, and implant removal.

Results: in total, 207 patients were evaluated, women to men ratio was 2:1 (144:63 cases). The mean age was 56 years (women 62 years, men 45 years). Volar surgical approach with volar locking plate osteosynthesis predominated (199 cases). The complication rate was 10% with implant-associated complications being the most common (3.7%). The implant removal rate was 17%. No surgical site infection (SSI) was detected. Closed incision negative pressure therapy (ciNPT) was applied in high-risk wounds.

Conclusion: Volar locking plate osteosynthesis is a method of choice with a low complication rate. Implant removal is not routinely indicated. Preventive application of ciNPT is beneficial in high-risk wounds, but diagnosis of fracture of the distal forearm according to the occurrence in our analysis is not essential for preventive use of NPWT, since the incidence of wound infection, in high-risk patients, is extremely low.

Keywords—fracture, distal radius, osteosynthesis, volar locking plate, SSI, ciNPT

INTRODUCTION

A Large number of patients suffer from SSI and other complications related to incisions each year, which result in their compromised well-being. There is a rising

number of more complicated surgical interventions due to the ageing population and increasing occurrence of multi-morbidities with a rising need for reducing incisional complications. Management of closed incisions can be successfully ensured by means of the negative pressure wound therapy (NPWT), which seems to be potential prophylaxis to reduce the incidence of incisional complications. Distal radius fractures represent approximately 19% of all fractures.¹ It is therefore the most common injury to the skeleton of the upper limb and, one of the most common fractures in traumatological practice.

The first work dealing with this injury can be found as early as the 18th century from French surgeons (Poteau, Petit). The rich history of treatment is also evidenced by the number of eponyms related to typical variants of these fractures, which are still used in the clinical practice to this day. Colles, Smith, or Barton fractures are still widely used. Of the more detailed classifications, AO, Fernandez, or Frykman are most often used clinically. Despite the considerable progress achieved in the development of angularly stable implants, conservative therapy continues to play an irreplaceable role in the treatment of this injury. Most patients thus benefit from closed reposition therapy and immobilization in a plaster bandage with subsequent rehabilitation care. In general, surgical treatment remains an option in case of unstable fractures that cannot be successfully corrected by closed repositioning or secondarily dislocated fractures.²

This work aims to evaluate the incidence of surgical treatment, their complications including surgical wound infections in distal-radio fractures.

PATIENT GROUP AND METHOD

The study group consisted of 207 patients with a distal radius fracture who were operated on at the authors' workplace between 1 January 2009 and 31 December 2018. The data were obtained retrospectively from the archives of the hospital clinical information system. We were interested in the age and gender of patients, the surgical approach, complications, including infection as well as in the frequency of extraction of metal material. The surgical solution was indicated for unstable fractures or upon failure of the conservative procedure, taking into account the general condition

Manuscript received 06.04.2021; revised 21.07.2021. This work did not receive any financial support.

Author affiliations: Surgical Clinic of St. Anne's University Hospital of Brno . (JH, MR, JK, MK, RH, LV)

*Correspondence to: Lenka Veverková: lenka.veverkova@fnusa.cz

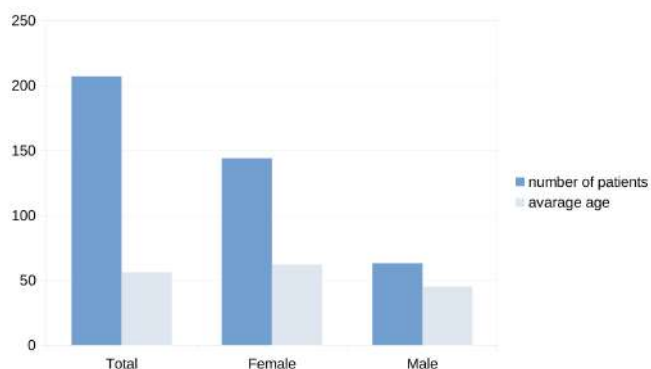


Figure 1. Total patient group and average age

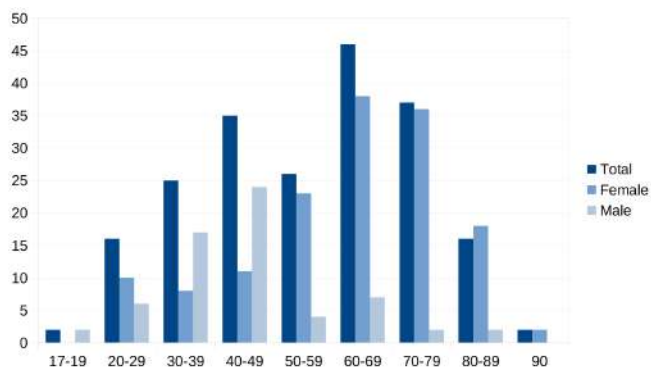


Figure 2. Overview of patients by age and gender

of the patient. When evaluating X-ray images, we based our judgment on the generally accepted signs of instability (initial dorsal angulation $>20^\circ$, volar angulation of the Smith fracture type, pronounced comminution of the dorsal cortical bone, intra-articular fracture with fracture of the distal ulna, the need for an extreme wrist position to retain fragments).² Surgery for simultaneous fractures of both distal forearms in the same patient and conversion of the external fixator to internal osteosynthesis (ORIF) were calculated separately.

RESULTS

A total of 1.410 patients with distal radius fractures were treated in our outpatient ward at our clinic during the 10-year period under review. A total of 207 patients (15%) forming the monitored group were indicated for surgical treatment. The age of patients ranged from 17 to 94 years and the average age was 56 years. In total, women (144 in total) outnumbered men (63 in total) by a ratio of 1:2 (Fig. 1), however, in the under-50 age group, we observed the predominance of men with an average age of 45 years. On the contrary, women with an average age of 62 already prevailed in the over-50 age group. The epidemiological data are summarised in detail in (Tab. I) and (Fig. 2).

Out 212 surgical interventions, the volar approach (modified Henry approach) prevailed, which was indicated in 199 cases (94%). The dorsal operational approach was chosen in only four cases. Stabilization by an external fixator had to be used in five cases and only once was the conversion to a volar

locking plate indicated. In the other four cases, an external fixator was a definitive way of treatment. In exceptional cases, a different procedure was chosen (transfixation with Kirschner wires). See (Tab.II) in summary.

Complications were observed in 21 patients, representing 10% of the total number of treatments. In eight cases, osteosynthesis failed. Neurological complications were observed in seven cases, most commonly palsy of the medianus (5 patients). Carpal tunnel syndrome was diagnosed in two patients. In addition, a lesion of the tendon was detected twice. Early infectious complications in the monitored population were not identified. Complications and their frequency are summarised in (Tab.III). The incidence of complication in our cohort was significantly different depending on the patient's gender, p-value — .03383. Women had more complications than men (Tab.IV).

Osteosynthetic material extraction was performed in 35 patients, representing 17% of the total group. The most common indication to remove metal material was to reduce pain upon mobility (10 patients). The other indications are clearly summarised in (Tab. V).

The functional result was evaluated postoperatively using the DASH score. Most achieved 15 points 12 months after osteosynthesis.

DISCUSSION

Regarding their frequency, fractures of distal radius represent not only a significant medical problem but also socio-economical one. In terms of incidence and age, bimodal distribution in these fractures is defined by a higher frequency in patients over 65 years of age and in the pediatric population under 18 years of age.³

Due to the age range of our monitored group, it is noticeable that we have recorded a peak incidence typical of older age (Fig. 2). If we take a closer look at the link between age and gender, we observed further bifurcation of this peak, with the greatest incidence of fractures in men under 50 years of age compared to the peak incidence in women over 60. An ageing population with a higher risk of osteoporosis, where a banal fall often leads to a fracture, undoubtedly contributes to the high frequency in women. On the other hand, we observe a higher incidence of fracture in men in their 50s, often as a result of high-energy trauma, typical for a younger age.³⁻⁵

Conservative therapy remains a dominant treatment of distal radius fractures. More than three-quarters of patients were treated in this way during our reference period. In a relatively recent study, Bruyere et al. compared conservative and surgical therapy of distal radius fractures in patients over 65 years of age. Although radiological results favor surgical therapy, the functional results are the same in the long run.⁶ In other words, we might say that the radiological picture fails to predict a functional result of treatment. Faster recovery in our group of operated patients has not been demonstrated. Moreover, if we take into account frequent severe comorbidities in patients of higher age, the risk of infection, and often patient's lower demand on function,

Table I
OVERVIEW OF PATIENTS OF THE MONITORED GROUP BY AGE AND GENDER

Age (yrs.)	Total		Female		Male	
	number	percentage	number	percentage	number	percentage
17-19	2	1.00%	0	0.00%	2	1.00%
20-29	16	8.00%	10	5.00%	6	3.00%
30-39	25	12.00%	8	4.00%	17	9.00%
40-49	35	17.00%	11	5.00%	24	12.00%
50-59	26	13.00%	23	11.00%	3	1.00%
60-69	46	22.00%	39	19.00%	7	3.00%
70-79	38	18.00%	36	17.00%	2	1.00%
80-89	16	8.00%	14	7.00%	2	1.00%
90+	3	1.00%	3	1.00%	0	0.00%
Total	207	100.00%	144	69.00%	63	31.00%

Table II
NUMBER OF OPERATIONS AND SURGICAL APPROACHES

Surgical Approach	Number	Percentage (%)
Volar approach	199	94
External fixator	5	2.4
Dorsal approach	4	1.8
Other	4	1.8
Total	212	100

Table III
COMPLICATIONS AND THEIR FREQUENCY

Complication	Number	Percentage (%)
Osteosynthesis failure	8	3.7
Paresis nervus medianus	5	2.3
Carpal tunnel syndrome	2	1
Complex regional pain syndrome	2	1
Tendon lesions	2	1
Dorsal prominence of screws (pain)	2	1
Infection	0	0
Total	21	10

Table IV
COMPLICATIONS AND THEIR STATISTICAL DEPENDENCE ON GENDER INCIDENCE

Complication	Yes	No	Marginal Totals (%)	Row
Men	5 (6.39 [0.3])	58 (56.61 [0.03])	63	
Women	16 (14.61) [0.13]	128 (129.39) [0.01]	144	
Total	21	186	207	

The chi-square statistic with Yates correction is 4.5033 (p-value = .03383).

Table V
METAL EXTRACTION BY INDICATION

Indication	Number	Percentage (%)
Unknown	13	6.3
Pain / limited movability	10	4.8
Removal of external fixation / K-wires	5	2.4
Release of osteoporosis material	2	1
Patient's wish	2	1
Nerve paraesthesia / deliberation	2	1
Tendon rupture	1	0.5
Total	35	17

non-operative therapy seems to be a rational choice. However, the basis of successful conservative therapy remains closed repositioning and retention of fragments throughout the healing period in plaster fixation. Fig. 3 – 6 document the course of conservative therapy of distal radio fractures from repositioning to the removal of plaster bandages.

Angularly stable locking plates currently represent the gold standard in the surgical treatment of distal radius fractures. Since a significant part of fractures can be treated by a volar approach, volar angularly stable implants (VLP) are often the method of choice. In our group, the vast majority of cases were treated this way (94%) (Fig. 7, – 9). This approach is popular due to its relative simplicity, clarity, and coverage of the plate with a layer of soft tissues with the assumption of good healing. Low occurrence of infection in the wound also plays an important role. The dorsal surgical approach using adequate angularly stable implants was preferred in only four cases. These were mostly communicative intraarticular fractures with dorsal segment impairment. In five cases, it was necessary to use a bridging external fixator as a method of choice. In four cases this represented the definitive treatment. Although this method may appear to be ultimum refugium in severely comminuted fractures, surprisingly good functional results comparable to ORIF are described in the literature, especially in the long term.⁷

In general, in these cases, the use of an external fixator supplemented by Kirschner wires is preferred. Transfixation by separate Kirschner wires is used only sporadically in the sense of mini-invasive adaptation osteosynthesis in at-risk patients, where it is complemented by a plaster fixation.

Due to the fact that the volar operating approach with implantation of the corresponding locking plate was the dominant method of fixation in our group, we can conclude that the incidence of complications also reflects the frequency of complications relating to this approach. In literature, we can encounter a great variability in the incidence of complications, practically from 0 to 60%, which is mainly due to the heterogeneity of studies and the different conception of the definition of complications. The recent systematic review of Alter et al. indicated the complication rate of 15% volar locking plate fixation method, of which 5% of the complications are serious with the need for reoperation.

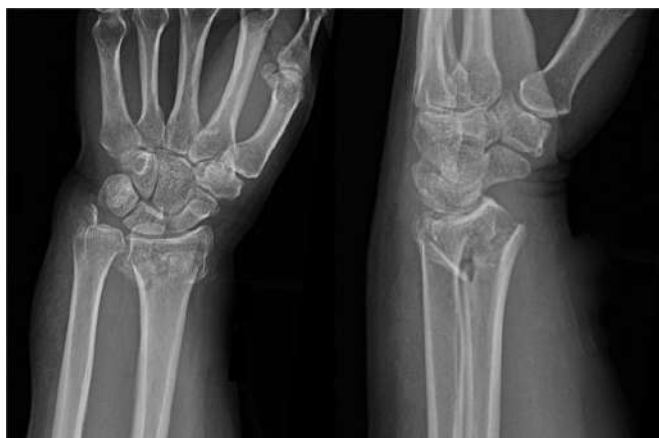


Figure 3. Fracture of distal radio in AP (left) and lateral (right) projection

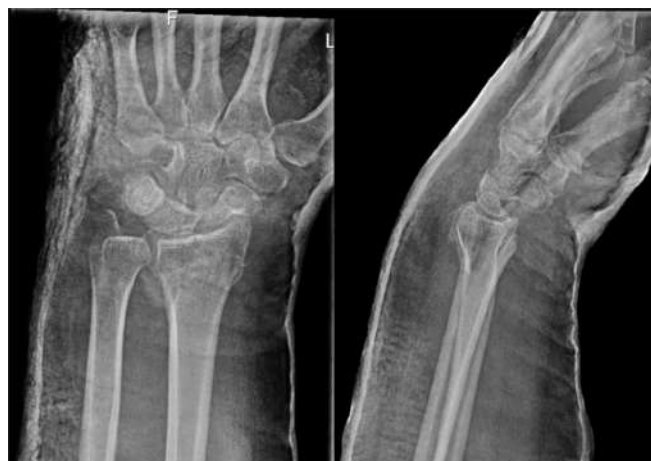

Figure 5. X-ray imaging 2 weeks after repositioning

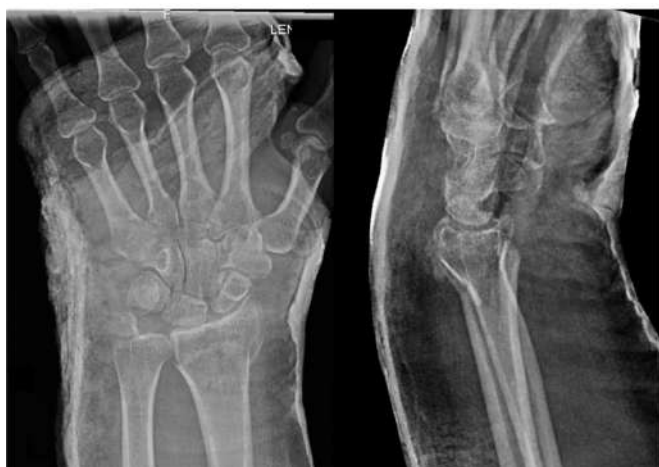

Figure 4. condition after closed repositioning of fracture and application of plaster fixation

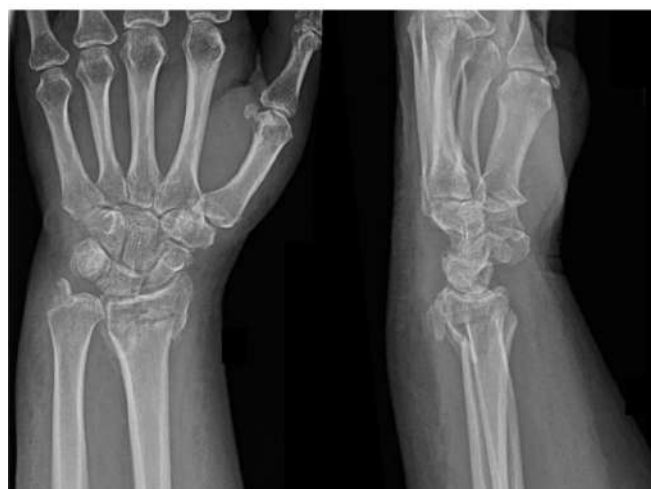


Figure 6. X-ray imaging after removal of plaster fixation and start of rehabilitation (5 weeks after repositioning)

Neurological complications with an indication of 5.7% are listed as the most common, including carpal tunnel syndrome and CRPS. It also lists tendon injuries (3.5%) and complications associated with the implant (1.6%).⁸ In our cohort, we observed complications in only 10% of cases, as illustrated in (Tab. III).

Most often it was osteosynthesis failure, in less than 4% of cases. Particularly problematic are the fractures affecting the most distant part of the cortical bone, where anatomical repositioning and stable fixation of the distal series of screws are difficult to achieve. Complications in these fractures can be avascular necrosis of small fragments of the joint area with intra-articular screw dislocation (Fig. 10). In the therapy of this complication, extraction of osteosynthetic material with subsequent rehabilitation care is indicated. Due to the fact that the joint surface is affected, the functional results tend to be worse than in extraarticular fractures. Of the neurological complications, the most common was a form of nervus medianus disability, from simple paresthesia to development of the carpal tunnel syndrome. We observed complex regional pain syndrome in two patients. Nerve deliberation was indicated in only one case. Nerve injury

can be a result of both fracture and medical treatment. It is therefore important to properly examine and document neurological status before initiation of any treatment.

Regarding the surgical solution of distal radio-fractures, we can see both tendon flexor injury and extensor injury. In particular, the tendon of the long thumb stretcher (EPL) is endangered due to its anatomical course both during the operation during the implant fixation and in the postoperative period as a result of dorsally prominent screws or insufficient repositioning of the dorsal cortical bone. We observe two cases of tendon injury (as we mention in the results — chart), one of which was an EPL tendon rupture, solved by surgical transposition. An operational revision with tendon surgery was indicated. Azzi *et al.* indicate an incidence of tendon affection after internal osteosynthesis of 6.8%. The frequency of tendon rupture when fixing with a dorsal and volar locking plate is almost the same (1.7 and 1.5%, respectively). Tendon injuries, especially extensors, are also described in conservative therapy.⁹

ECDC considers the surgical site infection (SSI) an infection occurring within 30 days of surgery, in the case of

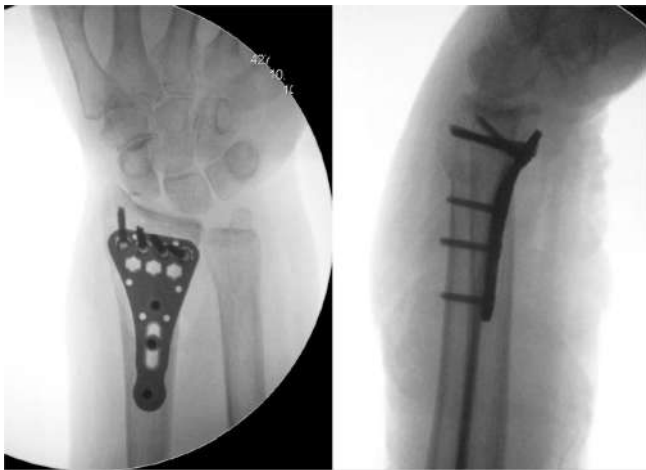


Figure 7. Osteosynthesis by means of volar angularly stable locking plate (postsurgery documentation)

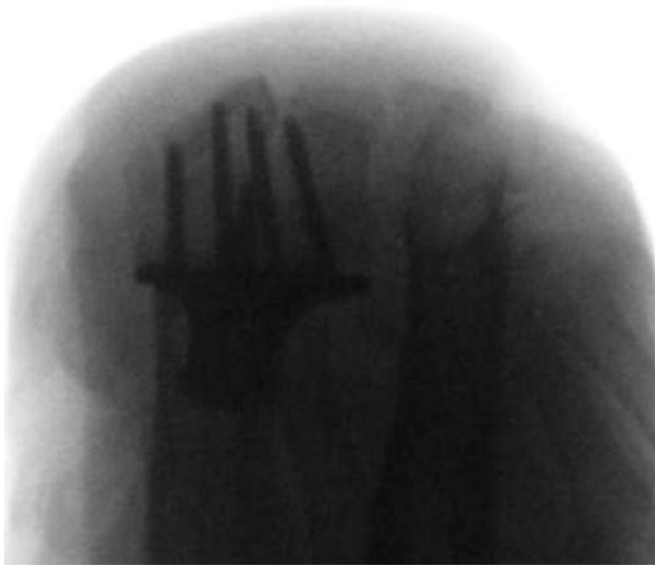

Figure 8. Radiological imaging of the distal screws ("Skyline" projection , post-surgical documentation)

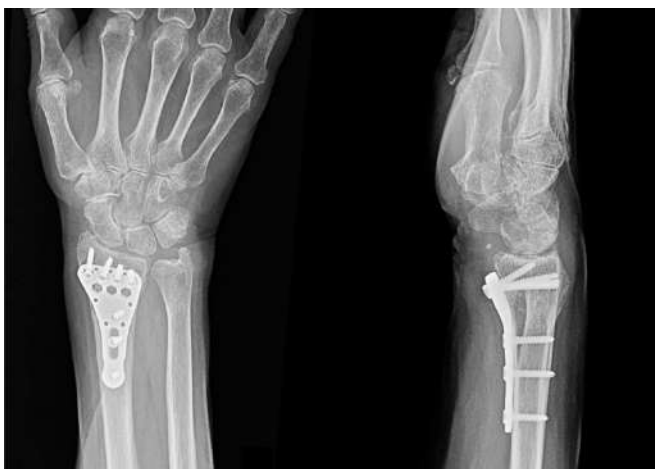

Figure 9. Radiological imaging following osteosynthesis (3 months)

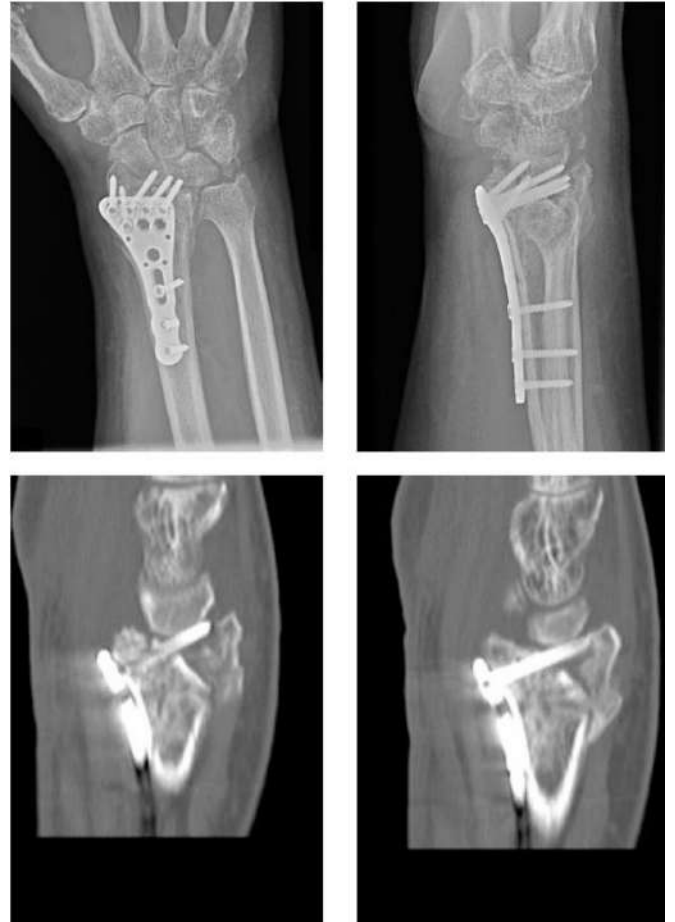

Figure 10. Intraarticular prominence of a distal screw line, X-ray projection AP and side (upper images), CT in sagittal incisions (bottom images)

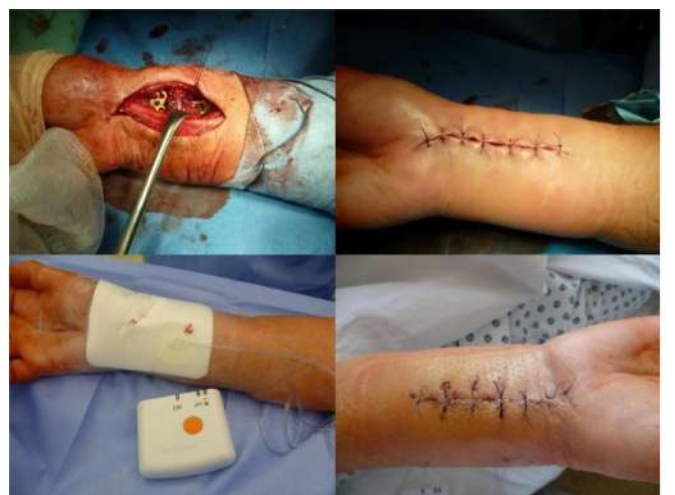

Figure 11. ciNPT system application and the therapeutic result

implanted foreign material within 90 days, provided that it is related to the surgery.¹⁰ Bacterial contamination with skin flora (*Staphylococcus* spp.) is the most common cause. In addition to the general principles of SSI prevention, antibiotic prophylaxis is recommended for pure interventions using an implant, which should be administered within 30 minutes prior to incision.^{11, 12}

At our clinic, based on the epidemiological situation and the recommendations of the antibiotic center, we administer one intravenous dose of cephalosporin of the 1st generation (Cefazolin) according to the patient's weight. Post-injury swelling and soft tissue bruising are also risk factors for the development of SSI. The preventive use of a negative pressure therapy applied to the primary suture (ciNPT or pNPWT) is an effective way to protect wounds with a high risk of infection. The potential benefits of ciNPT are in particular the reduction of stress in the wound, the reduction of swelling, the drainage of secretion, and the prevention of secondary bacterial contamination (Fig. 11). The advantages of this method in reducing postoperative infection have been described especially in patients with risk factors for SSI (obesity with BMI of 30 kg/m², diabetes mellitus, smoking, corticotherapy). Higher prices and poorer availability of the method in lower-class healthcare facilities are cited as disadvantages. The SSI rate was highest after external fixation and lowest after plate fixation^{11–15}

Due to the anatomical deposition of the volar locking plate and the relatively low number of complications, the extraction of metal material is quite rare. Yamamoto *et al.* in his systematic review indicate an average extraction rate of 9%, with no improvement in clinical status after extraction has been demonstrated.¹⁶ In our group, we present a total extraction frequency of 17% (35 patients). After subtraction of the necessary extractions (external fixator, Kirschner wires), with a frequency of 14.6% (30 patients), we are getting close to the incidence of complications. In general, the extraction of a volar locking plate at our clinic is not routinely carried out but is individually considered in justified cases.

Functional results after osteosynthesis by volar locking plates were rated very good in our cohort with an average DASH score comparable to other studies.^{17, 18} An interesting comparison of the functional results of conservative and surgical therapy with volar locking plates (VLP) is presented in the recent study of Li *et al.*, involving a total of 1189 patients in 11 studies. VLP therapy can improve grip strength and the radiological result.¹⁹

CONCLUSION

Distal radius fractures are some of the most common fractures in outpatient practice, especially in patients over 65 years of age. The majority of these injuries are still treated conservatively today with good functional results, which are comparable to the surgical solution with properly conducted treatment. We always consider the indications for the surgical performance individually, taking into account not only the radiological examination but also the general condition of the patient. The volar surgical approach with the implantation

of an angularly stable locking plate has proven to be an effective surgical method with a relatively low frequency of complications and good functional results. However, subsequent rehabilitation care has a dominant position in both conservative and surgical therapy. Preventive application of the negative pressure therapy system (ciNPT) in risk wounds has proven to be effective, although the incidence of infection in this type of fracture is not common despite the old age and comorbidities including high BMI. Extraction of a volar locking plate is not routinely recommended.

ACKNOWLEDGEMENT

We would like to thank the entire staff of the 1st Surgical Clinic of the St. Anne's University Hospital in Brno who participated in the treatment of patients.

REFERENCES

- [1] V. Báča, V. Džupa, and M. Krbec, *Diagnostika a léčba nejčastějších osteoporotických zlomenin*. Charles University in Prague, Karolinum Press, 2017.
- [2] V. Pokorný, *Traumatologie. 1st edition*. Prague: Triton, 2002.
- [3] N. J. MacIntyre and N. Dewan, "Epidemiology of distal radius fractures and factors predicting risk and prognosis," *Journal of Hand Therapy*, vol. 29, no. 2, pp. 136–145, 2016.
- [4] P. Wendsche and R. Veselý, *Traumatologie. Second, redesigned and extended edition*. Prague: Galén, 2019.
- [5] T. O. White, S. P. Mackenzie, and A. J. Gray, *McRae's Orthopaedic Trauma and Emergency Fracture Management*. Elsevier Health Sciences, 2015.
- [6] A. Bruyere, P. Vernet, S. S. Botero, Y. Igeta, J. J. H. Diaz, and P. Liverneaux, "Conservative treatment of distal fractures after the age of 65: a review of literature," *European Journal of Orthopaedic Surgery & Traumatology*, vol. 28, no. 8, pp. 1469–1475, 2018.
- [7] K. Egol, M. Walsh, N. Tejwani, T. McLaurin, C. Wynn, and N. Pak-sima, "Bridging external fixation and supplementary kirschner-wire fixation versus volar locked plating for unstable fractures of the distal radius: a randomized, prospective trial," *The Journal of bone and joint surgery. British volume*, vol. 90, no. 9, pp. 1214–1221, 2008.
- [8] T. H. Alter, K. Sandrowski, G. Gallant, M. Kwok, and A. M. Ilyas, "Complications of volar plating of distal radius fractures: a systematic review," *Journal of wrist surgery*, vol. 8, no. 03, pp. 255–262, 2019.
- [9] A. J. Azzi, S. Aldekhayel, K. S. Boehm, and T. Zadeh, "Tendon rupture and tenosynovitis following internal fixation of distal radius fractures: a systematic review," *Plastic and reconstructive surgery*, vol. 139, no. 3, pp. 717e–724e, 2017.
- [10] "European centre for disease prevention and control. surveillance of surgical site infections and prevention indicators in european hospitals: Hai net ssi protocol, version 2.2." 2017 accessed March 24, 2021. [Online]. Available: <https://data.europa.eu/doi/10.2900/260119>
- [11] "World health organization. global guidelines for the prevention of surgical site infection," 2016 accessed March 24, 2021. [Online]. Available: <https://apps.who.int/iris/bitstream/handle/10665/250680/9789241549882-eng.pdf?sequence=8>
- [12] "National institute for health and care excellence (great britain), national guideline centre (great britain). surgical site infections: prevention and treatment," 2019 accessed March 24, 2021. [Online]. Available: <https://www.ncbi.nlm.nih.gov/books/NBK542473/>
- [13] C. Willy, A. Agarwal, C. A. Andersen, G. D. Santis, A. Gabriel, O. Grauhan, O. M. Guerra, B. A. Lipsky, M. B. Malas, L. L. Mathiesen *et al.*, "Closed incision negative pressure therapy: international multidisciplinary consensus recommendations," *International Wound Journal*, vol. 14, no. 2, pp. 385–398, 2017.
- [14] L. G. Fernandez, M. R. Matthews, P. S. Alvarez, S. Norwood, and D. H. Villarreal, "Closed incision negative pressure therapy: review of the literature," *Cureus*, vol. 11, no. 7, 2019.
- [15] J. Rundgren, A. Enocson, H. Järnbert-Pettersson, and C. M. Navarro, "Surgical site infections after distal radius fracture surgery: a nationwide cohort study of 31,807 adult patients," *BMC Musculoskeletal Disorders*, vol. 21, no. 1, pp. 1–10, 2020.

- [16] M. Yamamoto, Y. Fujihara, N. Fujihara, and H. Hirata, "A systematic review of volar locking plate removal after distal radius fracture," *Injury*, vol. 48, no. 12, pp. 2650–2656, 2017.
- [17] C. Bartl, D. Stengel, F. Gebhard, T. Bruckner, and S. G. ORCHID, "The treatment of displaced intra-articular distal radius fractures in elderly patients: a randomized multi-center study (orchid) of open reduction and volar locking plate fixation versus closed reduction and cast immobilization," *Deutsches Ärzteblatt International*, vol. 111, no. 46, p. 779, 2014.
- [18] J. Saving, S. S. Wahlgren, K. Olsson, A. Enocson, S. Ponzer, O. Sköldenberg, M. Wilcke, and C. M. Navarro, "Nonoperative treatment compared with volar locking plate fixation for dorsally displaced distal radial fractures in the elderly: a randomized controlled trial," *JBJS*, vol. 101, no. 11, pp. 961–969, 2019.
- [19] Q. Li, C. Ke, S. Han, X. Xu, Y.-X. Cong, K. Shang, J.-D. Liang, and B.-F. Zhang, "Nonoperative treatment versus volar locking plate fixation for elderly patients with distal radial fracture: a systematic review and meta-analysis," *Journal of Orthopaedic Surgery and Research*, vol. 15, no. 1, pp. 1–9, 2020.