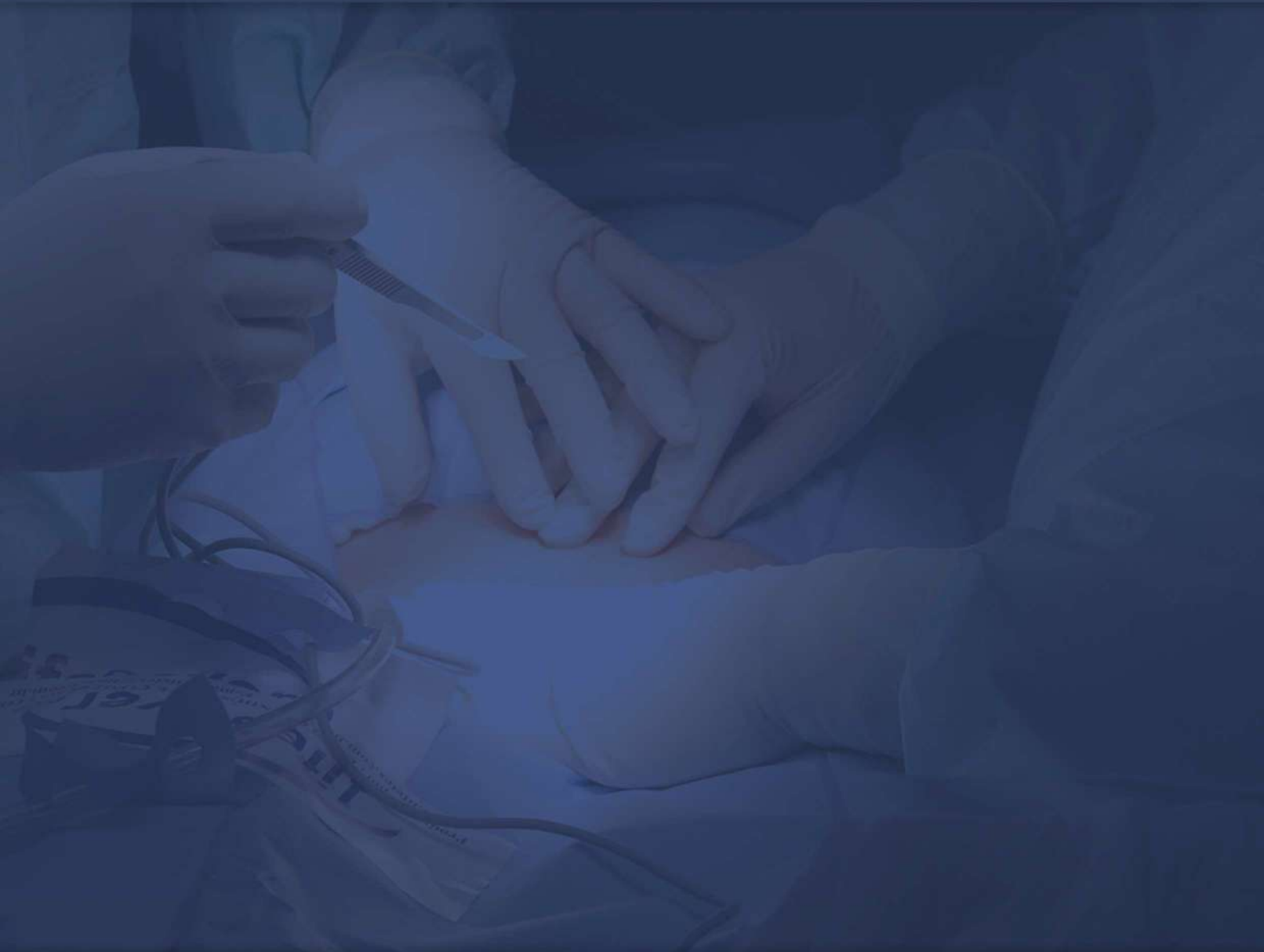

# NEGATIVE PRESSURE WOUND THERAPY JOURNAL

VOLUME 6

| ISSUE 4

| DECEMBER 2019



## JOURNAL EDITORIAL BOARD

Editor in Chief Prof. Tomasz Banasiewicz	Poznań, Poland	Dr. Mankowski Bartosz Prof. Marciniak Ryszard Prof. Niezgoda Jeffrey A. Prof. Malinger Stanisław Prof. Oszkiniś Grzegorz Prof. Pramod Kumar Prof. Georgi Popivanov, Prof. Runkel Norbert Prof. Salomone Di Saverio, Prof. Sopata Maciej Prof. Szejsza Jacek Prof. Toth Csaba Dr. Trueman Paul Dr. Trzeciak Piotr Prof. Siemionow Maria Prof. Stojcev Zoran Dr. Sukhbir Singh New Prof. Szczepkowski Marek Prof. Szentkereszty Zsolt Dr. Dominik Walczak Prof. Wallner Grzegorz Prof. Wild Thomasz Prof. Veverkova Lenka Prof. Angel Zorraquino Prof. Zhou Ye-ping Dr. Zieliński Maciej	Poznań, Poland Poznań, Poland West Allis, USA Poznań, Poland Poznań, Poland Saudi Arabia Sofia, Bulgaria Villingen-Schwenningen, Germany Bologna, Italy Poznań, Poland Poznań, Poland Debrecin, Ungarn Hull, UK Belchatow, Poland Cleveland, USA Słupsk, Poland Delhi, India Warszawa, Poland Debrecin, Ungarn Łódź, Poland Lublin, Poland Hamburg, Germany Brno, Czech Republic Bilbao, Spain Beijing, China Poznań, Poland
Statistics Editor Prof. Elżbieta Kaczmarek Managing Editor Wojciech Francuzik Editorial Board Prof. Becker Rolf Dr. Bobkiewicz Adam Dr. Borejsza Wysocki Maciej Prof. Cirocchi Roberto Dr. Cybułka Bartosz Prof. Drews Michał Prof. Duteille Franck Prof. Dżiki Adam Prof. Fraccalvieri Marco Prof. Heiney Jake P. Prof. Hudson Donald Prof. Hutan Martin Prof. Ichioka Shigeru Prof. Kościński Tomasz Dr. Krokowicz Łukasz Prof. Krokowicz Piotr Prof. Larichev B. Andreia Prof. Mike G. Laukoetter	Poznań, Poland Poznań, Poland Poznań, Poland Köln, Germany Poznań, Poland Poznań, Poland Perugia, Italy Gorzów Wielkopolski, Poland Poznań, Poland Nantes, France Łódź, Poland Torino, Italy Lambertville, USA Cape Town, South Africa Bratislava, Slovakia Saitama, Japan Poznań, Poland Poznań, Poland Poznań, Poland Jaroslav Russi Muenster, Germany		

### PUBLISHER

The Medigent Foundation deals with the introduction of new technologies in medicine. Mobile applications that support doctors' decisions are of particular importance to us. To date, the Foundation has completed several projects with international partners creating new solutions in the field of medicine and new technologies. We would like to invite all interested parties to cooperate: innovators, doctors and new partners, to create new tools and solutions for medicine.

Medigent - A foundation in which doctors create solutions for doctors

### SUBSCRIPTIONS

Negative Pressure Wound Therapy Journal is published quarterly by Medigent Foundation in Poland.

All content is publicly available free of charge on the [www.npwtj.com](http://www.npwtj.com) webpage. Readers who would like to be notified of new issues may register using a form on [www.npwtj.com](http://www.npwtj.com).

### COPYRIGHT

All works published in this journal are shared under Creative Commons 4.0 Attribution Licence unless specified otherwise.

Statements and opinions expressed in the articles and communications are those of the individual contributors and not the statements and opinion of the Publisher.

### DISCLAIMER

We take no responsibility or liability for any damage or injury to persons or property arising out of the use of any materials, instructions, methods or ideas contained herein. We expressly disclaim any implied warranties of merchantability or fitness for a particular purpose.

### CONTACT INFORMATION

#### Address:

Negative Pressure Wound Therapy Journal,  
Clinic of General Surgery, Gastroenterologic  
Oncology and Plastic Surgery,  
Przybyszewskiego 49, 60355, Poznań

**Telephone:** +48 61-869-12-75

**Fax:** +48 61-869-16-84

**Electronic mail:** [editor@npwtj.com](mailto:editor@npwtj.com)

**Web:** [www.npwtj.com](http://www.npwtj.com)

#### Publisher:

Medigent Foundation NIP: 779 245 69 65  
ul. Grunwaldzka 66/2 Poznań, 60-311 Poland  
[www.medigent.org](http://www.medigent.org)

### TRADEMARKS

Trademarked names appearing in the pages of NPWTJ are property of their owners. The following list should not be considered complete: V.A.C. is a trademark of Kinetic Concepts, Inc.; Pico is a trademark of Smith & Nephew.

### ACKNOWLEDGEMENTS

Cover: Joanna Francuzik

### SUBMISSIONS

Editors of NPWTJ welcome all authors to submit their works for publication in the NPWTJ journal. We provide a thorough peer review and best recognition of your work. Send your work to our office by logging into our website: [www.npwtj.com](http://www.npwtj.com). Please use our online form to speed up the process.

---

TABLE OF CONTENTS

---

CASE REPORTS

THE ROLE OF NEGATIVE PRESSURE WOUND THERAPY IN THE MANAGEMENT OF ORO-CUTANEOUS FISTULAS IN CANCER PATIENTS – A CASE SERIES

*Iwona A. Niedzielska, Katarzyna M. Ścisła, Michał M. Bak, Damian Niedzielski* ..... 4

REVIEW

NEGATIVE PRESSURE WOUND THERAPY (NPWT) IN BREAST SURGERY

*Abdalla Saad Abdalla Al-Zawi, Vanessa Salih, Amira Asaad, Rebecca Harsten, Momen Abdou Alkhair, Hamad BenRafe, Tomasz Banasiewicz* ..... 10

# The role of Negative Pressure Wound Therapy in the management of orocutaneous fistulas in cancer patients – a case series

Iwona A. Niedzielska, Katarzyna M. Ścisła, Michał M. Bąk, Damian Niedzielski

## CASE REPORT

**Abstract—Background:** Negative Pressure Wound Therapy (NPWT) is used in the treatment of various wounds. The study demonstrates a novel use of vessel patch as a sealant of mucosal orifice fistulas.

**Methods:** The study included ten patients with orocutaneous fistulas in the course of treatment of oral malignancies. Patients were divided into treatment (NPWT) and control (conventional dressings) group. In four cases, the vessel patch was applied. We used the Hartmann Vivano system with 50 mmHg to 130 mmHg negative pressure values.

**Results:** The median age of patients was 61.5 years (range: 31 – 73 years). The median treatment time was 83 days (range: 14 – 272 days). The median total treatment cost was 5.300 EUR (range: 2490 – 7821 EUR) in the NPWT group and 12.000 EUR (range: 3.060 – 22.745 EUR) in the control group.

**Conclusion:** The use of NPWT is a cost-effective and reasonable method for the management of orocutaneous fistulas and other complications in maxillofacial surgery.

**Keywords—**NPWT, orocutaneous fistulas, cancer,

### INTRODUCTION

THE frequency of cutaneous fistulas formation after reconstruction surgery of head and neck varies between 2% to 66%.<sup>1</sup> Frederick et al. reported this complication in 3% of cases in their retrospective study carried out on 1,000 patients with the use of free vascularized tissue grafts.<sup>2</sup> Sousa et al. noted that among patients who underwent a total laryngectomy, the incidence of fistula formation was 15%, and it was the most common complication in this group of patients. The mean time to fistula formation was 3.5 days, with a standard deviation of 13.7 days. Malnutrition, positive surgical margins, the necessity of neck dissection, the presence of tracheostomy, tumor stage, and prior radiotherapy are considered to be contributing factors to fistula formation. However, a mechanistic dependency between those factors and fistula incidence has not been demonstrated.<sup>3</sup>

Moreover, surgical reconstruction promoting insufficient vascular viability of the tissues, poor suturing technique failing to provide watertight connection, and the contamination from the upper gastrointestinal tract contribute to fistula

Manuscript received 28.10.2019; revised 19.12.2019. This work did not receive any financial support.

Author affiliations: Department of Cranio-Maxillofacial Surgery, Medical University of Silesia, Francuska 20/24, 40-027 Katowice, Poland, (IN, KŚ, MB, DN)

\*Correspondence to: Michał Bąk: mmwbak@gmail.com

formation.<sup>4</sup> Orocutaneous and pharyngocutaneous fistulas cause serious inconvenience for patients. Applying dressings or covering them is widely restricted, and they may impede oral feeding.<sup>1</sup>

Furthermore, the occurrence of fistulas prolongs hospitalization time, raise therapy costs, and may postpone adjuvant therapy.<sup>5</sup> There is an agreement that cutaneous fistulas should be initially treated conservatively with antibiotics, wound cleansing with the application of conventional dressings, and transition to enteral feeding.<sup>3,5</sup> A fraction of fistulas responds to this type of treatment. Sousa et al. reported successful closure by nonsurgical means in all cases.<sup>3</sup> Nevertheless, McNeal et al. reported that spontaneous closure of pharyngocutaneous fistulas occurred after an average of 50 days (range: 10 – 120 days) among all the patients and 24 days (range: 14 – 60 days) in patients who did not receive radiotherapy.<sup>6</sup> Still, some fistulas do not respond to conservative treatment and require surgical treatment.<sup>5,7</sup>

Lately, the usefulness of Negative Pressure Wound Therapy (NPWT) in the treatment of orocutaneous and pharyngocutaneous fistulas was discussed by Andrews et al.<sup>8</sup> in 2008, Dhir et al.<sup>9</sup> in 2009, Tay et al.<sup>10</sup> in 2011 in a case report, Tian et al.<sup>5</sup> in 2013 in a study based on Tay report, Yang et al.<sup>4</sup> in 2013 and Kojima et al.<sup>7</sup> in 2015. In this latest study, Kojima et al. sutured the cutaneous side of fistulas to achieve airtightness and applied negative pressure of –200 mmHg.<sup>7</sup> On the other side, Yang et al. emphasized the necessity of suturing the mucosal side of the fistula.<sup>4</sup> Tay et al. and Tian et al. achieved the seal on the mucosal side of the fistula with cotton gauze immersed in the dental alginate impression material.<sup>5,10</sup> In this paper, we present a novel method of sealing the mucosal side of the fistula with the use of a non-resorbable vessel patch. The application of the vessel patch facilitates the watertight suturing on the mucosal side of the fistula, thus stopping the salivary leak into the fistula.

This solution has the following advantages:

- 1) facilitates watertight suturing on the mucosal side of fistula avoiding unnecessary tension,
- 2) allows watertight suturing in the situation of tissue deficit when it is impossible to repair the defect by primary closure
- 3) brings together and stabilizes wound margins, and
- 4) provides a watertight seal, thus stopping the saliva

leakage independently of the NPWT usage on the cutaneous side.

The last one simplifies the conventional wound care because dressings are loaded with less exudate. It is worth noting that (5) once sutured, the vessel patch stays in place and does not require replacement when the cutaneous dressings are changed (these can be either conventional or NPWT).

We have not found any prior reports on such usage of vessel patches in the literature. Vessel patches or vascular prostheses are commonly used in cardiac and vascular surgery in the treatment of injuries, aneurysms, congenital defects, and repairing defects of vessels and cardiac walls.<sup>11</sup> They are produced from biocompatible synthetic polymers or autologous, allogenic, or xenogenic pericardium.<sup>12</sup> Polyethylene terephthalate (PET), and Polytetrafluoroethylene (ePTFE) have been used in cardiac surgery due to their mechanical properties and satisfactory durability.<sup>11, 12</sup> This paper aims to evaluate the usefulness of NPWT and its combination with a vessel patch application in the management of orofacial fistulas in head and neck cancer patients.

## MATERIALS AND METHODS

### A. Patients

The study included patients with orofacial fistulas treated in the dep of Cranio-Maxillo-Facial and Oral Surgery of Silesian Medical University in Katowice between 2012 and 2014. Patients were divided into two groups: the treatment group (NPWT) and the control group (conventional dressings).

The inclusion criteria were:

- 1) the presence of orofacial fistula verified with dye test and
- 2) lack of possibility or indications for surgical management of the fistulas. The study included ten patients.

### B. Wound management

Physicians performed all the wound care procedures. NPWT dressings were changed every two to three days, and the conventional dressings were changed every day. The diagnosis of orofacial fistula was based on clinical examination and confirmed by the dye test with iodopovidone. The mucosal orifice of the fistula was flushed with water iodopovidone solution Braunol (B.Braun, Melsungen, Germany). In the presence of an orofacial fistula, iodopovidone solution appeared on the skin surface. In all cases, mucosal orifices were identified. In order to seal the mucosal opening of the fistula and to stop the saliva leakage in 4 cases (1, 2, 6, 7) the vessel patch was tightly sutured to the margins of the mucosal orifice with the use of polypropylene monofilament sutures (Dafilon, B.Braun, Melsungen, Germany). We present an application of vessel patch as a mucosal side sealant of orofacial fistulas.

The use of the vessel patch allowed us to maintain the pressure necessary to facilitate an effective NPWT in the wound bed. Moreover, in both treatment and control groups, the application of the vessel patch ceased the saliva seepage.

Shape stability of the vessel patch provides stabilization for fistula margins and increases the tendency to intraoral component closure by keeping margins closer to each other. In the control group the cutaneous side of the fistula was managed conventionally with silver dressings Aquacel Ag (ConvaTec, Bridgewater Township, NY, USA), Atraumann Ag (Paul Hartmann, Heidenheim an der Brenz, Germany), alginate dressing Sorbalgon (Paul Hartmann, Heidenheim an der Brenz, Germany) and iodopovidone or 10% NaCl compresses. In the treatment group, the NPWT dressing was applied on the cutaneous side of the fistula.

Before the introduction of the NPWT, necrotic tissues were removed from the wounds by surgical necrotomy. We used special wound dressings — Tender Wet (Paul Hartmann, Heidenheim an der Brenz, Germany) or lavaseptics with the use of an aqueous solution of octenidine and phenoxyethanol — Octenisept (Schülke & Mayr, Norderstedt, Germany). The NPWT system used in this study was Vivano (Paul Hartmann, Heidenheim an der Brenz, Germany) consisting of vacuum producing device VivanoTec, exudate canister VivanoTec, VivanoTec Port with multi-lumen drain and VivanoMed dressing kit. The dressing used in this study was the black microporous polyester polyurethane VivanoMed Foam. The sterile foam dressing was adjusted to wound shape, and then it was sealed with semipermeable Hydrofilm foil. Due to the complex anatomy of the head and neck and the presence of foramina, which reduced the surface available for sticking the foil, it was vital to shave the facial hair and degrease the skin meticulously. The latter was achieved by using Kodan Tinktur forte (Schülke & Mayr, Norderstedt, Germany). Hydrofilm foil prevents the infection by maintaining the moisture and simultaneously stops the growth of anaerobic bacteria due to its permeability. In order to avoid skin maceration, the skin at the margins was protected with Atraumann Ag (Paul Hartmann, Heidenheim an der Brenz, Germany) or Grassoind (Paul Hartmann, Heidenheim an der Brenz, Germany) dressings. Patients were administered empirical or targeted antibiotics. No drugs reducing salivary output were used. The research was approved by the Medical University of Silesia Local Ethics Board.

## RESULTS

The study included ten patients who developed ten orofacial fistulas. The group consisted of seven men and three women with a median age of 61.5 years (range, 31 – 73 years). Three patients had no comorbidities (3, 6, 10). The rest suffered from cardiovascular diseases. Moreover, one patient (5) was diagnosed with asthma-COPD overlap syndrome and chronic rhinosinusitis; the other one (8) was also treated for non-insulin-dependent diabetes mellitus. One patient also suffered from Osler-Weber-Rendu disease complicated with secondary anemia.

Regarding the type of surgery that led to complications, it can be said that orofacial fistulas formed in patients who underwent: (1) segmental resection of mandible with free nonvascularized hip bone graft reconstruction and a locking plate together with selective neck dissection in four cases (1,

Table I  
PATIENT DEMOGRAPHICS AND TUMOR CHARACTERISTICS

#	Age/ sex	Smoker	Comorbidities	Family history	Previous HNSCC	Prior RT	Pathology	TNM	Type of surgery
1	64/F	Y	IHD, HT, cardiac arrhythmia	Mother: thyroid cancer Sister: CNS tumor	No	No	SCC of the floor of mouth	T4N2cM0	Segmental resection of mandible. Reconstruction with free nonvascularized hip bone graft and reconstruction locking plate. SND.
2	65/M	Former	IHD, brady- cardia	Father: laryngeal cancer	SCC of cheek	60 Gy 11 months earlier	Osteoradionecrosis of the mandible body and ramus	N/A	Sequestrectomy and fis- tula closure.
3	67/M	Y	No	No	No	No	SCC of the floor of mouth	T4N2aM0	Segmental resection of mandible. Reconstruction with reconstruction locking plate. SND.
4	73/M	N	HT, cardiac arrhythmia, PAD, Post CABG	No	No	Yes*	SCC of the cheek	T2N2bM0	Resection of cheek tu- mor. Segmental resection of mandible. Reconstrec- tion with reconstruction locking plate.
5	64/M	Y	Prostate can- cer RT treat- ment	No	No	No	SCC of the floor of mouth	T3N1M0	Segmental resection of the mandible. Reconstruction with reconstruction lock- ing plate and Bakamijan flap. SND.
6	31/M	Y	No	No	No	No	Ameloblastoma of the mandible body in the area from 37 to 32	N/A	Segmental resection of mandible. Reconstruction with free nonvascularized hip bone graft and reconstruction locking plate. SND.
7	55/M	Former	HT	Mother: CNS tu- mor	No	No	SCC of the floor of mouth	T4aN2bM0	Segmental resection of mandible. Reconstruction with free nonvascularized hip bone graft and reconstruction locking plate. SND.
8	59/F	Y	NIDDM, HT	Mother: leukemia, Brother: laryngeal cancer, Sister: uterine cancer	No	No	SCC of the floor of mouth	T2N2cM0	Segmental resection of mandible. Reconstruction with reconstruction locking plate. SND.
9	47/M	Y	HHT, secondary anemia, HT,	Mother and grandfather: HHT, Great- grandfather: laryngeal cancer	No	No	SCC of the floor of mouth	T2N2bM0	Resection of tumor of oral cavity. SND.
10	59/K	Y	No	No	No	Yes (no medical records)	SCC of the floor of mouth	T3N2aM0	Segmental resection of mandible. Reconstruction with free nonvascularized hip bone graft and reconstruction locking plate. SND.

ACOS — asthma-COPD overlap syndrome, CABG — coronary artery bypass graft, HHT — Hereditary hemorrhagic telangiectasia, Osler-Weber-Rendu disease, HT — hypertension, IHD — ischaemic heart disease, NIDDM — non-insulin-dependent diabetes mellitus, PAD — peripheral artery disease, SCC — squamous-cell carcinoma, SND — selective neck dissection, \*Interrupted because of reconstruction plate exposure

Table II  
WOUND THERAPY CHARACTERISTICS

#	Intraoral site	Extraoral site	Additional treatment	Fistula formation (days) <sup>§</sup>	NPWT time (days)	NPWT settings	Vessel patch Y/N	Treatment time (days)	Costs
1	Floor of mouth	Incision in submental region	No	5	31	Continuous mode: -100, -85 mmHg	Y	31	T: 7.600€ D: 124€
2	Mucosa of cheek	Incision in submandibular region	No	3	36	Continuous mode: -50, -75, -85, -90 mmHg	Y	180*	T: 7.821€ D: 463€
3	Retromolar trigone	Incision in buccal region	No	7	31	Continuous mode: -125 mmHg	N	39	T: 5.300€ D: 434€
4	Floor of mouth	Submental region — formation of suppurative fistula	Removal of reconstruction plate. Surgical fistula closure	during RT	38	Continuous mode: -85, -120, -130 mmHg	N	272	T: 2.490€ D: 533€
5	Floor of mouth	Neck incision	No	9	14	Continuous mode -125 mmHg	N	25	T: 3.500€ D: 300€
6	Floor of mouth	Neck incision	Surgical fistula closure	15	0	No NPWT	Y	133	T: 3.060€ D: 13€
7	Floor of mouth	Neck incision	Removal of free bone graft. Surgical fistula closure	6	0	No NPWT	Y	78	T: 22.745€ D: 7€
8	Floor of mouth	Incision in submandibular region	No	10	0	No NPWT	N	180	T: 12.000€ D: 57€
9	Floor of mouth	Neck incision	No	6	0	No NPWT	N	14	T: 7.397€ D: 8€
10	Floor of mouth	Incision in submental region	Removal of reconstruction plate. Surgical fistula closure	4	0	No NPWT	N	83	T: 14.987€ D: 21€

T — total treatment cost, D — dressings cost, RT — radiotherapy group and 463 euro (range, 124 – 1282 EUR) in NPWT group. All above-mentioned values were calculated with the exchange rate of 4,20 PLN for 1 EUR, patient stopped showing up to our outpatient clinic. Time from surgery to fistula formation (days)

6, 7, 10); (2) segmental resection of mandible with locking plate reconstruction, together with selective neck dissection in cases (3, 4, 8); (3) resection of squamous cell carcinoma of the floor of the mouth in one case (9); (4) surgical treatment of osteoradionecrosis of mandible caused in the course of adjuvant radiation therapy for oral carcinomas in 2 cases (2, 5); (5) segmental resection of mandible with free nonvascularized hip bone graft reconstruction using a locking plate in the course of ameloblastoma treatment in one case (6). Median time from surgery to fistula diagnosis was six days (range, 3 – 15 days). In one case (4), the fistula formed in the course of radiation therapy and the cutaneous orifice revealed as a suppurative fistula in the submental region. In all the other cases, the cutaneous orifice of fistulas formed in surgical incisions.

Patient demographics and tumor characteristics are presented in (Tab. I). Nine of 10 patients were hospitalized due to squamous cell carcinoma or complications of its treatment, whereas one patient (6) was treated because of ameloblastoma of the mandible. Seven patients (1, 3, 4, 6, 7, 8, 10) underwent segmental resection of the mandible, two (2, 5) underwent sequestrectomy, and one (9) underwent resection of tumor of the oral cavity. Selective neck dissection was performed on seven patients (1, 3, 4, 7, 8, 9, 10). In four cases (1, 6, 7, 10), reconstruction of resected mandible was performed with free nonvascularized hip bone graft and reconstruction locking plate, while in three cases (3, 4, 8),

the reconstruction plate was used standalone. One patient underwent a tracheotomy. Treatment time was defined as the time between fistula diagnosis and complete wound healing recorded in patients' medical history. For one patient (2), recorded treatment time represents the time from fistula diagnosis to the time he stopped showing up to our outpatient clinic has not, and we excluded it from the statistical analysis. The median treatment time was 83 days (range, 14 – 272 days) for all patients, whereas, in the NPWT group, it was 94.5 days (range, 31 – 272 days). The median time in the control group was 83 days (range, 14 – 180 days). The specific data on wound therapy characteristics are shown in (Tab. II). In two patients in the NPWT group, it was necessary to apply the vessel patch in order to obtain a vacuum seal. Once sutured in place, vessel patch facilitated vacuum generation in wound bed regardless of NPWT dressings changes. Besides, the vessel patch was applied in two patients from the control group, which protected the lumen of fistula from salivary infection.

In all patients from the treatment group, the NPWT system Vivano (Paul Hartmann, Heidenheim an der Brenz, Germany) was used. The continuous mode of therapy was used, and the negative pressure values ranged from -50 mmHg to -130 mmHg. In one patient (5), additionally, the dynamic mode of therapy was employed with the cycles of 5 minutes at -80 mmHg and subsequently 5 minutes at -120 mmHg. In one case (2), there was a need to downgrade the negative pressure

value because of the painful burning sensation reported by the patient. In two patients from the control group (6, 7), in whom the NPWT was not employed, and in one patient (4) from the NPWT group, it was necessary to perform additional surgical procedures in order to close the fistulas finally.

Furthermore, for all the patients, we performed the analysis of total treatment costs regarding the cost of hospital stay, operating theater, and dressing materials used. This data is presented in (Tab. II). The median of the total treatment cost for all patients was 7498.5 EUR (range, 3.060 – 22.745 EUR); in the control group, it was 12.000 EUR (range, 3.060 – 22.745 EUR) whereas in NPWT group it was 5.300 EUR (range, 2490 – 7821 EUR). Median of dressing materials cost was 90.5 EUR (range, 7 – 1282 EUR) for all patients, 13 EUR (range, 7 – 57 EUR) in the control group, and 463 EUR (range, 124 – 1282 EUR) in NPWT group. All the values mentioned above were calculated with the exchange rate of 4.20 PLN for 1 EUR.

## DISCUSSION

Nowadays, Negative Pressure Wound Therapy is commonly applied in orthopedic traumatology, soft tissue injuries, management of skin grafts, treatment of pressure ulcers, diabetic foot, venous ulcers, and burns. NPWT also aids in fighting against Surgical Site Infections and treatment of Impaired Wound Healing.<sup>13</sup> The literature data on NPWT application in the treatment of cutaneous fistulas in the head and neck region consists of papers by Andrews et al.,<sup>8</sup> Dhir et al.,<sup>9</sup> Tay et al.,<sup>10</sup> Tian et al.,<sup>5</sup> Yang et al.,<sup>4</sup> and Kojima et al.<sup>7</sup> Yang et al. emphasize that the application of NPWT may constitute a useful indicator of mucosal side water tightness, moreover by obliteration of dead spaces, it prevents the damage of large vessels and reduces the total treatment cost. In general, NPWT is depicted by Yang et al. as a convenient treatment modality for orocutaneous fistulas, which facilitates infection control and fistula obliteration.

Tian et al. strongly recommend the use of NPWT in the treatment of orocutaneous fistulas, as none of the patients in their study experienced side effects of NPWT. Moreover, the authors indicate that the development of NPWT complications may result from either inappropriate patient selection or an incorrect NPWT application manner.<sup>5</sup> Our observation is similar to the authors mentioned above – the median of total treatment cost in the NPWT group is lesser than in the control group, and the complication of NPWT usage in the form of pain and burning sensation was eliminated by more accurate surrounding skin protection. The study by Kojima et al. stands slightly in opposition to Yang et al. and Tian et al. studies, and our observation. They reported the lack of seal of NPWT dressings even when the negative pressure value was lowered to –200 mmHg. As a reason, the authors indicate: (1) complex outline of the wounds; (2) presence of facial hair; (3) the proximity to tracheostomy; (4) the communication of fistula with oral cavity and/or pharynx; (5) reduced tissue elasticity due to prior radiation therapy. Moreover, in this study, the use of NPWT raised the total therapy cost because of elongating the hospitalization time.<sup>7</sup>

Our observation indicates that achieving the water tightness on the mucosal side of the fistula and thorough shaving of facial hair and skin degreasing provided sufficient seal for the dressings. Indeed after three days, the facial hair in males started to impair the dressing seal. Nevertheless, it seems that before the mentioned time, it is irrelevant.

The action of NPWT is based on (1) draining the pathological exudates from the wound bed,<sup>14–27</sup> (2) reducing the edema,<sup>15–18, 20, 21, 25–28</sup> and maintaining the humid environment.<sup>16, 17, 25, 29</sup> The positive effect of NPWT on leukocytes and fibroblasts migration<sup>22, 27, 30</sup> and accumulation of growth factors<sup>27, 30</sup> has been demonstrated. Lower concentrations of metalloproteinases (MMPs)<sup>31</sup> and raised levels of interleukin 8 (IL-8) and vascular endothelial growth factor (VEGF)<sup>18</sup> have been observed. Analysis performed by Glass et al. stated that NPWT significantly reduces tumor necrosis factor (TNF) concentration in acute and chronic wounds and interleukin 1 beta (IL-1 $\beta$ ) in acute wounds while having no influence on interleukin 6 (IL-6) levels. NPWT raises interleukin 10 (IL-10) systemic levels and interleukin 8 (IL-8) tissue concentrations. It raises VEGF and basic fibroblast growth factor (bFGF, FGF2) excretion and reduces the expression of metalloproteinases 1, 2, 9, and 13.<sup>32</sup> This treatment modality enhances wound blood supply<sup>15–17, 17–20, 23, 24, 27, 33</sup> by angiogenesis stimulation.<sup>16, 18–20, 25, 33, 34</sup> Worth noting is remarkably significant influence of this therapy on proliferation of cells,<sup>18, 19, 25</sup> granulation tissue formation<sup>14–20, 24, 25, 29, 33, 34</sup> and epithelialization.<sup>18, 20</sup> Moreover NPWT leads to wound area reduction<sup>9</sup> by contraction of wound margins.<sup>14, 16, 18, 19, 25</sup> The optimal negative pressure value is –125 mmHg.<sup>14–19, 22, 25, 30</sup> Regarding the expected effect of therapy, this value can be changed.<sup>14</sup> According to literature data immediately upon surgical wound debridement, it is recommended to set negative pressure values between –150 mmHg and –200 mmHg, however, for the granulation tissue formation stimulation, it is advisable to lower the values to –110 mm Hg to –130 mmHg.<sup>21</sup>

There are reports on the use of negative pressure values not exceeding –80 mmHg in order to minimize the possible tissue injury.<sup>22</sup> Furthermore, the cases were described in which the negative pressure values were set to –50 mmHg in the therapy of ischemic wounds (Critical Limb Ischemia) providing satisfactory results without wound margins necrosis<sup>23</sup> According to Malmjö et al., there are no significant differences in wound healing between negative pressure values of –50 mmHg, –75 mmHg, and –125 mmHg. Furthermore, the blood flow at –80 mmHg is similar to that at –125 mmHg. In conclusion, the authors suggest the use of higher pressure values in painful wounds with poor blood supply<sup>13</sup> Because of the anatomic factors NPWT in the region of head and neck is not straightforward in use; however, it is highly efficient in the treatment of impaired wound healing. Undoubtedly further investigation on the mechanism of action of NPWT is warranted. Likewise, there is little evidence on the use of NPWT in orocutaneous fistulas treatment, and further trials should be conducted. In this paper, we described a novel method of sealing a mucous-end fistula orifice preventing



the salivary penetration. The dressings in the NPWT group were changed every 2 to 3 days, which turned out to be both cost-effective and convenient for patients.

#### CONCLUSIONS

The application of Negative Pressure Wound Therapy is a reasonable treatment modality for complications in maxillo-facial surgery, including orofacial fistulas.

#### REFERENCES

- [1] P. L. Sadigh, C.-J. Wu, W.-J. Feng, C.-H. Hsieh, and S.-F. Jeng, "New double-layer design for 1-stage repair of orofacial and pharyngocutaneous fistulae in patients with postoperative irradiated head and neck cancer," *Head & neck*, vol. 38, no. S1, pp. E353–E359, 2016.
- [2] J. W. Frederick, L. Sweeny, W. R. Carroll, G. E. Peters, and E. L. Rosenthal, "Outcomes in head and neck reconstruction by surgical site and donor site," *The Laryngoscope*, vol. 123, no. 7, pp. 1612–1617, 2013.
- [3] A. A. Sousa, J. Porcaro-Salles, J. Soares, J. Carvalho, G. Silva, P. Savassi-Rocha *et al.*, "Predictors of salivary fistula after total laryngectomy," *Revista do Colegio Brasileiro de Cirurgioes*, vol. 40, no. 2, pp. 98–103, 2013.
- [4] Y.-H. Yang, S.-F. Jeng, C.-H. Hsieh, G.-M. Feng, and C. C. Chen, "Vacuum-assisted closure for complicated wounds in head and neck region after reconstruction," *Journal of Plastic, Reconstructive & Aesthetic Surgery*, vol. 66, no. 8, pp. e209–e216, 2013.
- [5] B. Tian, D. Khoo, A. C. Tay, K.-C. Soo, N. C. Tan, H. K. Tan, and N. G. Iyer, "Management of orofacial fistulas using a vacuum-assisted closure system," *Head & neck*, vol. 36, no. 6, pp. 873–881, 2014.
- [6] J. N. Mclean, C. Nicholas, P. Duggal, A. Chen, W. G. Grist, A. Losken, and G. W. Carlson, "Surgical management of pharyngocutaneous fistula after total laryngectomy," *Annals of plastic surgery*, vol. 68, no. 5, pp. 442–445, 2012.
- [7] M. Kojima, J. Yokoyama, S. Ooba, M. Fujimaki, T. Anzai, and *et al.*, "Problems associated with vacuum-assisted closure system in postoperative head and neck fistula," *J Otol Rhinol*, vol. 0, no. 1, 2015.
- [8] B. T. Andrews, R. B. Smith, H. T. Hoffman, and G. F. Funk, "Orofacial and pharyngocutaneous fistula closure using a vacuum-assisted closure system," *Annals of Otolaryngology, Rhinology & Laryngology*, vol. 117, no. 4, pp. 298–302, 2008.
- [9] K. Dhir, A. J. Reino, and J. Lipana, "Vacuum-assisted closure therapy in the management of head and neck wounds," *The Laryngoscope*, vol. 119, no. 1, pp. 54–61, 2009.
- [10] A. Tay, C. Ong *et al.*, "Management of a complex mandibular wound: a case study," *Wound Practice & Research: Journal of the Australian Wound Management Association*, vol. 19, no. 3, p. 110, 2011.
- [11] A. M. Ostried, J. R. Ivey, S. A. Hansen, R. Gopaldas, and S. A. Grant, "Feasibility of a nanomaterial-tissue patch for vascular and cardiac reconstruction," *Journal of Biomedical Materials Research Part B: Applied Biomaterials*, vol. 104, no. 3, pp. 449–457, 2016.
- [12] C. Yang, "Tissue engineering of human cardiovascular patches." Ph.D. dissertation, Charité - University Medicine, Berlin., 2005.
- [13] M. Malmström and O. Borgquist, "Npwt settings and dressing choices made easy," *Wounds International*, vol. 1, no. 3, 2010.
- [14] M. Zieliński and W. Majewski, "Współczesne koncepcje leczenia ran przewlekłych," *Wounds International*, vol. 9, no. 1, pp. 74–81, 2009.
- [15] D. A. Caniano, B. Ruth, and S. Teich, "Wound management with vacuum-assisted closure: experience in 51 pediatric patients," *Journal of pediatric surgery*, vol. 40, no. 1, pp. 128–132, 2005.
- [16] M. Shirakawa and R. R. Isseroff, "Topical negative pressure devices: use for enhancement of healing chronic wounds," *Archives of dermatology*, vol. 141, no. 11, pp. 1449–1453, 2005.
- [17] Ł. Woda, Z. Banaszkiewicz, and A. Jawień, "Terapia podciśnieniowa w leczeniu trudno gojących się ran," *Leczenie Ran*, vol. 9, no. 4, 2012.
- [18] A. Wackenfors, J. Sjögren, R. Gustafsson, L. Algotsson, R. Ingemansson, and M. Malmström, "Effects of vacuum-assisted closure therapy on inguinal wound edge microvascular blood flow," *Wound repair and regeneration*, vol. 12, no. 6, pp. 600–606, 2004.
- [19] S. S. Scherer, G. Pietramaggiore, J. C. Mathews, M. J. Prsa, S. Huang, and D. P. Orgill, "The mechanism of action of the vacuum-assisted closure device," *Plastic and reconstructive surgery*, vol. 122, no. 3, pp. 786–797, 2008.
- [20] D. A. Simhaee, A. Marsano, G. M. Fomovsky, G. Niedt, J. K. Wu *et al.*, "Efficacy and mechanisms of vacuum-assisted closure (vac) therapy in promoting wound healing: a rodent model," *Journal of Plastic, Reconstructive & Aesthetic Surgery*, vol. 62, no. 10, pp. 1331–1338, 2009.
- [21] J. Taradaj, A. Franek, C. Kucio, and K. Walewicz, "Terapia podciśnieniowa (vac) w leczeniu trudno gojących się ran," *Rehabilitacja w praktyce*, vol. 3, pp. 42–44, 2010.
- [22] M. Miller, "Mcdaniel c," *Leczenie rzeźnięcia się rany przy pomocy alternatywnego systemu powierzchniowego wywierania podciśnienia. Leczenie Ran*, vol. 4, no. 4, pp. 125–129, 2007.
- [23] Y. Kasai, H. Nemoto, N. Kimura, Y. Ito, and N. Sumiya, "Application of low-pressure negative pressure wound therapy to ischaemic wounds," *Journal of Plastic, Reconstructive & Aesthetic Surgery*, vol. 65, no. 3, pp. 395–398, 2012.
- [24] J. E. Grey, K. G. Harding, R. Mądry, M. Sierociński, J. Strużyna, and P. Wydawnictwo Lekarskie, *Leczenie ran w praktyce*. Wydawnictwo Lekarskie PZWL, 2010.
- [25] C. Huang, T. Leavitt, L. R. Bayer, and D. P. Orgill, "Effect of negative pressure wound therapy on wound healing," *Current problems in surgery*, vol. 51, no. 7, pp. 301–331, 2014.
- [26] I. BABIAK, "Negative pressure wound therapy (npwt) and its role in the treatment of infected wounds in orthopedic practice," *Leczenie Ran*, vol. 11, no. 1, 2014.
- [27] I. Babiak, M. Ł. Żakiewicz, and M. Luterek, "Zastosowanie opatrunków podciśnieniowych vac w kompleksowym leczeniu otwartych złamań i iib i iic podudzia z masywnym ubytkiem tkanek miękkich," *Chir. Narz. Ruchu Ortop. Pol.*, vol. 76, no. 3, pp. 154–160, 2011.
- [28] J. P. Stannard, D. A. Volgas, G. McGwin III, R. L. Stewart, W. Obrensky, T. Moore, and J. O. Anglen, "Incisional negative pressure wound therapy after high-risk lower extremity fractures," *Journal of orthopaedic trauma*, vol. 26, no. 1, pp. 37–42, 2012.
- [29] B. MROZIKIEWICZ-RAKOWSKA, A. NOWAK, E. BUCIOR, J. KANIA, K. GŁODAŁA-JAKONIUK, and P. KRASNODĘBSKI, "Zastosowanie terapii podciśnieniowej w leczeniu zespołu stopy cukrzycowej," *Leczenie Ran*, vol. 11, no. 1, 2014.
- [30] I. BABIAK, "Negative pressure wound therapy (npwt) and its role in the treatment of infected wounds in orthopedic practice," *Leczenie Ran*, vol. 11, no. 1, 2014.
- [31] C. M. Mouës, A. W. Van Toorenbergen, F. Heule, W. C. Hop, and S. E. Hovius, "The role of topical negative pressure in wound repair: expression of biochemical markers in wound fluid during wound healing," *Wound repair and regeneration*, vol. 16, no. 4, pp. 488–494, 2008.
- [32] G. Glass, G. Murphy, A. Esmaili, L.-M. Lai, and J. Nanchahal, "Systematic review of molecular mechanism of action of negative-pressure wound therapy," *British Journal of Surgery*, vol. 101, no. 13, pp. 1627–1636, 2014.
- [33] S. Lindstedt, M. Malmström, J. Sjögren, R. Gustafsson, and R. Ingemansson, "Impact of different topical negative pressure levels on myocardial microvascular blood flow," *Cardiovascular Revascularization Medicine*, vol. 9, no. 1, pp. 29–35, 2008.
- [34] L. Labler, M. Rancan, L. Mica, L. Härter, D. Mihic-Probst, and M. Keel, "Vacuum-assisted closure therapy increases local interleukin-8 and vascular endothelial growth factor levels in traumatic wounds," *Journal of Trauma and Acute Care Surgery*, vol. 66, no. 3, pp. 749–757, 2009.

# Negative Pressure Wound Therapy (NPWT) in Breast Surgery

Abdalla Saad Abdalla Al-Zawi, Vanessa Salih, Amira Asaad, Rebecca Harsten, Momen Abdou Alkhir, Hamad BenRafe, Tomasz Banasiewicz

## REVIEW

**Abstract— Background:** The use of Negative Pressure Wound Dressing has been found to promote the wound healing process, therefore, reducing the risk of surgical site complications. The use of this technique amongst breast cancer patients, who have often encountered a distressing journey, may prove beneficial in making the post-operative process less eventful. Many of these patients have a limited time window to start adjuvant treatment. The use of a negative pressure device is recommended in both prophylactic and therapeutic scenarios. NPWT may also be used in patients who have undergone cosmetic breast surgery. We have evaluated the use of NPWT in breast surgery with an updated and systematic review of the available literature.

**Methods:** The authors systematically searched the PubMed, Science Direct, and Wiley Online databases using the phrases “Negative Pressure Wound Therapy in Breast surgery” and “Vacuum-Assisted Closure in Breast Wound” and all publications, including relevant data were considered eligible for inclusion in the review.

**Results:** We have found reports of 7 studies, 3 retrospective, 2 prospective, one randomized trial, and one case series. The complication rate in the NPWT group versus conventional dressing group has been reported in 5 papers. A statistically significant effect in favor of NPWT was documented in three trials.

**Conclusion:** The current evidence supports the notion that NPWT systems are beneficial in enhancing the healing of complicated breast wounds. However, larger studies exploring the effectiveness of this technique would be of interest to breast surgeons.

**Keywords—**Negative Pressure Wound Therapy, vacuum-assisted closure, Breast cancer, Breast reconstruction

## INTRODUCTION

THE scope of breast surgery includes the management of benign and malignant breast disease either by mastectomy with or without reconstruction (autologous tissue as well as implant-based) or breast conservative surgery.

Manuscript received 03.08.2019; revised 17.12.2019. This work did not receive any financial support.

Author affiliations: Department of Surgery, Basildon & Thurrock University Hospital, Essex, United Kingdom, (ASAA, AA)

; Department of Surgery, Kings College Hospital, London, United Kingdom, (VS); Lewisham and Greenwich NHS Trust, London- United Kingdom, (RH); Morzoque Faculty of Medical Technology, Sebha University – Libya, (MAA); Faculty of Medicine, Omar Al-Mukhtar University, Al-Baida-Libya, (HB); Department of General, Endocrine Surgery and Gastrointestinal Oncology, Poznań University of Medical Sciences, Poznań, Poland, (TB)

\*Correspondence to: Abdalla Saad Abdalla Al-Zawi: abdalasaad@gmail.com

Furthermore, it also encompasses aesthetic surgery such as breast augmentation or reduction. Complications associated with the post-operative wound-healing process remain one of the most common challenges and are potentially associated with delaying adjuvant therapy and diminishing the aesthetic result.

The benefits of using the Negative Pressure Wound Dressing in Breast surgery have been well documented.

Breast cancer is considered the most frequently detected female malignancy worldwide and the dominant cause of cancer-related mortality amongst women.<sup>1</sup> Although breast surgery is typically associated with a low risk of surgical site infection (SSI), the use of the Negative Pressure Wound Dressing further results in a favorable outcome.

We have studied available data that discuss the effectiveness of negative pressure wound therapy (NPWT) systems in the management of post-surgical wounds involving the breast.

## METHODS

The PRISMA principles have been followed during this review preparation. The PubMed, Science Direct, Wiley Online databases, and Scopus databases have been searched systematically. All the papers that revealed relevant data were considered eligible for inclusion in the review.

## INCLUSION CRITERIA

We have looked at studies involving patients that underwent surgical breast procedures. The intervention under exploration was the use of NPWT in postoperative wounds. The comparator treatment was conventional dressings including dry wound dressing, alginate dressings or saline-soaked gauze dressings. Original papers such as randomized controlled trials (RCTs), retrospective studies, prospective studies, and case series have been included and the full text of the paper was explored. Papers that do not refer to the use of NPWT in breast surgery were excluded. The primary outcome was complete wound closure. No minimum patient sample size per trial was required and no restriction was placed for study dates or periods. After selection, seven original research papers met the inclusion criteria and were finally included in this review, (one randomized trial, three cohort retrospective studies, two prospective studies, and one

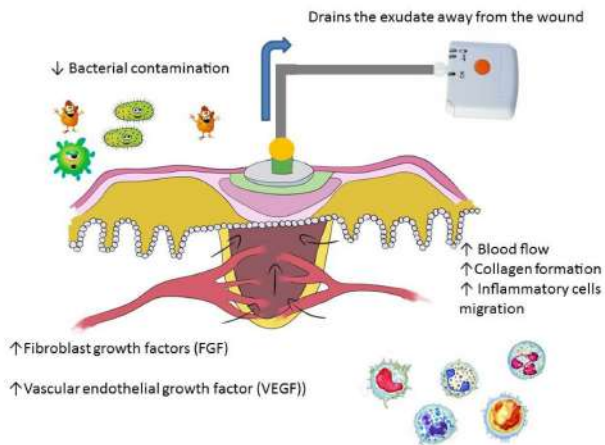


Figure 1. Mechanism of action in negative pressure wound therapy. Modified from Bruke *et al.* 2014

case series). The studies involved 492 female patients treated with NPWT versus 584 patients treated with conventional dressing methods.

## RESULTS

### A. Mechanism of action

The use of Negative Pressure Wound Dressing promotes wound healing by triggering several healing pathways *i.e.* angiogenesis which improves tissue oxygenation and aids migrating the inflammatory cells to the healing site. It also aids the diversion of the wound exudate away from the wound and promotes patient independence and improves quality of life.<sup>2-4</sup>

### B. Device types and indications

The current devices that provide NPWT are vacuum-assisted closure (VAC) system and PICO™ dressing. The PICO™ dressing is a canister free; single-use topical NPWT system that maintains  $-80$  mmHg pressure (Fig. 2). The NPWT systems are used to manage complex wounds such as those which are infected, diabetic foot ulcers, post-traumatic wounds, burns, and necrotizing fasciitis.<sup>5</sup>

NPWT concept is continually evolving. In addition to the use of conventional NPWT it may also be used to manage post-surgical wound complications or as a prophylactic measure to reduce the infection risk.<sup>6</sup> Negative Pressure Wound Therapy with the installation system (NPWTi) has also been developed. It incorporates the traditional NPWT and a local irrigation system within the wound cavity. NPWTi significantly reduces the growth of biofilm that colonize the wound cavity. Such formation of biofilm is considered to be one of the main factors impairing the wound healing process.<sup>7</sup>

Stoeckel *et al.* retrospectively analyzed the data of 18 patients who had post-operative breast wound complications treated with NPWT. 15 of the patients underwent surgery for breast cancer, two had reduction mammoplasty, and one

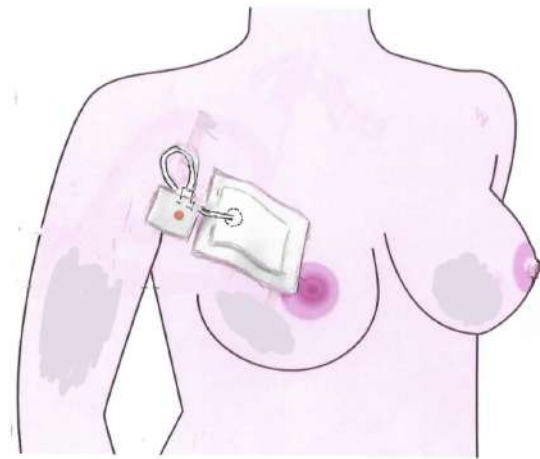


Figure 2. PICO™ dressing in breast surgery

was treated for a recurrent primary breast abscess. 12 of the 15 cancer patients underwent mastectomy had subsequent breast reconstruction procedures. Seven wounds were related to implant or tissue expander placement. Four patients had complicated transverse rectus abdominus myocutaneous (TRAM) flap wounds, and one had a latissimus dorsi flap wound. 15 of 18 patients were treated effectively using NPWT. Two patients required muscle flap coverage. The hospital stay ranged from 3 to 54 days with a mean of 12.1 days. NPWT dressing has been used to promote wound healing after skin grafting, or as a mean to prepare the wound for surgical closure. Seven of the wounds healed by secondary intention, six were successfully treated with subsequent skin grafting, and two were treated with delayed primary closure. Two wounds were both complicated by tissue ischemia and infection requiring operative debridement (Tab. I). The authors concluded that vacuum-assisted closure therapy promotes faster healing and stimulates the formation of healthy granulation tissue.<sup>8</sup>

### C. NPWT in oncoplastic breast surgery boosts incision closure

Holt and Murphy from South Manchester University Hospital conducted a study to assess if the application of negative pressure wound therapy dressings (PICO™) on closed incisions in patients undergoing therapeutic resection promotes superior wound healing. 24 consecutive patients (over 20 months) were included in the study. They either underwent a therapeutic mammoplasty or skin-sparing mastectomy and immediate reconstruction with inferior dermal flap and implant placement. All patients had a simultaneous symmetric breast reduction at the same sitting. The therapeutic procedure side was supplied with PICO™ dressings while the opposite breast reduction was dressed with conventional dressings. The overall rate of wound dehiscence was 4.2% ( $n = 1$ ) on the therapeutic procedure side compared with 16.7% ( $n = 4$ ) on the contralateral breast reduction side. The mean time to complete healing was 10.7 days in the therapeutic side treated with PICO™ compared with 16.1

days on the contralateral side. One mastectomy patient had delayed wound healing at the T-junction on both sides (Tab. I). The authors concluded that this evidence further supports the use of NPWT in oncoplastic breast procedures, as it reduces the rates of wound dehiscence, boosts healing, and allows commencement of adjuvant therapy.<sup>9</sup>

Ferrando et al. conducted a prospective study that included 37 cases. ciNPT was used in 17 cases (46%), whereas the remaining 20 (54%) had conventional post-operative wound dressing. The difference in complication rate between the 2 groups was significant, the ciNPT sample showed complication rates of only 1/25 (4%), as compared to 45% (10 out of 22) in the standard care group (Tab. I). The study outcome supports the use of ciNPT in oncological breast surgery. Furthermore, the dressing is well-tolerated, adaptable, and has shown to improve scar outcomes especially in patients presenting with high-risk factors.<sup>10</sup>

Gabriel et al. investigated closed incision Negative Pressure Therapy (ciNPT) with a customizable dressing on 13 patients (25 breasts) who received immediate postmastectomy reconstruction as part of 2-stage expander/implant breast reconstruction. Nipple-sparing mastectomy was performed on 14 breasts, reduction-pattern mastectomy on 6 breasts, and skin-sparing mastectomy on 5 breasts. All post-mastectomy incisions were managed with ciNPT. The single-use therapy unit provided continuous negative pressure (-125 mmHg) with a replaceable 45 ml exudate canister. The wound dressing and ciNPT unit were designed for placement for up to 7 days. Surgical drains were routed under the skin beyond the ciNPT dressing and they functioned independently of ciNPT. The majority of patients (56.0%) were treated with nipple-sparing mastectomy. Overall mean ciNPT duration ranged from 3 to 5 days. The mean drain placement was 8.2 days. After three months follow-up, 96% (24/25 breasts) achieved complete healing. Superficial dehiscence occurred in 12% (3/25 breasts), and flap necrosis occurred in 4% (1/25 breasts) in the breast reduction-pattern group. One patient from the nipple-sparing mastectomy group developed a delayed hematoma postoperatively. No superficial wound dehiscence required surgical intervention. One obese, diabetic patient developed a flap necrosis which required surgical revision. All other breasts healed and remained closed at 3-month follow-up (Tab. I). The paper concluded that ciNPT could be a viable option for wounds after immediate post-mastectomy reconstruction.<sup>11</sup>

In a cohort of 206 patients (228 breasts), Kim et al. examined the usefulness of the ciNPT to reduce mastectomy flap necrosis in immediate expander-based breast reconstruction. The incisional-NPWT group (45 breasts) had a lower overall complication rate in comparison with a conventional dressing group (11.1% vs. 27.9%,  $p = 0.019$ ). In detail, the overall mastectomy flap necrosis rate was 8.9 % (versus 23.5 %;  $p = 0.030$ ), and major mastectomy flap necrosis rate was 2.2 % (versus 13.7 %;  $p = 0.031$  compared with the conventional dressing group, Tab. I). The paper concluded that the use of NPWT is an effective method in reducing mastectomy flap necrosis in expander-based breast reconstruction.<sup>12</sup>

Gabriel et al. conducted a retrospective study comparing

postoperative outcomes in patients who were treated with ciNPT versus standard of care (SOC) after breast reconstruction following mastectomy procedures. The authors investigated the medical records of 356 patients (ciNPT = 177, SOC = 179) with 665 closed breast incisions (ciNPT = 331, SOC = 334). Overall complication rate was 8.5% (28/331) in ciNPT group compared with 15.9% (53/334) in SOC group ( $p = 0.0092$ ). Compared with the SOC group, the ciNPT group had significantly lower infection rates (7/331 (2.1%) versus 15/334 (4.5%), respectively;  $p = 0.0225$ ). Time to complete drain removal per breast for ciNPT versus SOC groups was 9.9 versus 13.1 days ( $p < 0.0001$ ), respectively. Patients who received ciNPT over closed incisions following mastectomy and breast reconstruction experienced a shorter time to surgical drain removal and significantly lower rates of infection, dehiscence, necrosis, and seromas, compared with the SOC group.<sup>13</sup>

#### D. NPWT in breast surgery transplants

Angspatt et al. in 2017 evaluated the efficacy of NPWT in preventing donor site seroma formation after the harvest of a latissimus dorsi muscle flap for breast reconstruction. It was a prospective matched-pair study, 40 patients were included. 20 patients had NPWT dressing at the donor site, and conventional wound dressing was used in the control group ( $n = 20$ ). In the NPWT group, seroma incidence after the drain removal was significantly lower than in the control group (15% vs. 70%; odds ratio = 0.07, relative risk, 0.24). Both the mean percutaneous aspirated volume ( $p = 0.004$ ) and the frequency of percutaneous aspirations ( $p = 0.001$ ) were also significantly lower in the NPWT group (Tab. I). The paper concluded that the use of NPWT reduces the seroma incidence after drain removal from the latissimus dorsi flap harvesting site.<sup>14</sup>

#### E. ciNPT after reduction mammoplasty decreases wound dehiscence risk

Galiano et al. presented a multinational, prospective, randomized, open trial to evaluate the efficacy of PICO™ (canister free; single-use NPWT system) on the prevention of post-surgical incision healing complications in 200 patients undergoing bilateral reduction mammoplasty (Tab. I). One patient arm was treated with PICO™ on one breast and Steri-strips on the contralateral side. This group was assessed for local wound complications three weeks after the operation. Secondary objectives were to assess post-surgical complications (such as skin necrosis, hematoma, wound dehiscence and seromas), scar quality and the ease of application of PICO™ versus standard wound care. The outcome revealed a trend towards fewer complications and adverse events in the PICO™ group compared to conventional wound care. Results also found a 38% decrease in wound dehiscence, which was statistically significant.<sup>15</sup>

#### F. Complex cases

NPWT can also be used to manage complex postoperative complications relating to breast implant placement such as

Table I  
NPWT IN BREAST ONCOPLASTIC SURGERY

Author	Age range	Patient number, Breast number	Complications rates in NPWT vs. Conventional methods	Mean NPWT duration (days)	Outcome
Stoeckel et al. 2006 Retrospective study	Mean 52	T:18, (18) C: 0, (0)	no data	15	Fifteen of the 18 patients were definitively treated with the VAC
Holt et al. 2015 case series	42–70	T: 24, (24) C: 24, (24)	1/24 (4.2%) vs. 4/24 (16.7%)	6	The study further supports the use of negative pressure wound therapy on incised wounds
Gabriel et al. 2016 retrospective cohort study	27–62	T: 13, (26) C: 0, (0)	5/26 (19%) vs. no data	4.3	By 3-month follow-up 24 of 25 (96%) breasts achieved healing.
Kim et al. 2016 prospective cohort study	34–49	T :44, (45) C: 162, (183)	5/45 (11.1%) vs. 51/183 (27.9%)	3	The use of NPWT in patients who underwent breast reconstruction significantly reduced the incidence rates of overall wound related complications.
Galiano et al. 2018 international, RCT	18–65	T: 199, (199) C: 199, (199)	113 (56.8%) vs. 123 (61.8%)	14	NPWT group had fewer healing complications than the conventional dressing group
Gabriel et al. 2018 retrospective cohort study	40–64	T: 177, (331) C: 179, (334)	28 (8.5%) vs. 53 (15.9%)	9	Patients who received ciNPT over closed incisions experienced significantly lower rates of wound complications, compared with the SOC group
Ferrando et al. 2018 prospective cohort study	no data	T: 17, (25) C: 20, (22)	1/25 (4%) vs. 10/22 (45%)	7	The results support the use of ciNPT in oncological breast surgery

\* ciNPT; Closed Incision Negative Pressure Therapy, SOC: Standard Care of Therapy The complications included superficial dehiscence, skin flap necrosis infection, seroma, haematoma and exposed implant, T: Patients treated with NPWT methods, Breasts number, C: Patients treated with conventional methods, Breasts number, RCT - randomized control trial

implant exposure after Acellular Dermal Matrix (ADM) reconstruction or following Nipple Area Complex (NAC) — sparing mastectomy. The NPWT allows for a rapid implant replacement after the implant pocket infection has been resolved.<sup>16, 17</sup> Risk factors promoting surgical site infections include high BMI, diabetes mellitus, hypoalbuminemia, smoking, status post-chemotherapy, COPD, anemia, and immune-compromised patients. NPWT provides a safe alternative in such populations.

### G. Surgical Site Infection and NPWT

It has been reported that NPWT, when applied prophylactically to a closed surgical wound, results in a decrease in the incidence of wound complications such as infection or collection of fluid.<sup>15</sup> Strugala et al., in 2017, conducted a meta-analysis to determine the impact of prophylactic use of NPWT on SSI, wound dehiscence and length of hospital stay. The outcome revealed a significant reduction of SSI from 12.5% to 5.2% with NPWT use. Wound dehiscence rate was reduced from 17.4% to 12.8% with NPWT, and the mean reduction in hospital length of stay (in patients treated with NPWT) was also significant (−0.47 days). Such observations also encourage the use of NPWT in a wide range of abdominal, orthopedic and colorectal procedures.<sup>18</sup>

Post-operative wound-related complications following breast surgery varies from 7 to 31% in the literature.<sup>19, 20</sup>

Consequences include a prolonged hospital stay, delay in adjuvant treatment delivery, poor cosmesis, the need for further surgery and increased management costs. Furthermore, the use of negative pressure wound dressing and its associated benefits in reducing complications plays a part in easing a patient's psychological stress in the post-operative period.

### CONCLUSION

One in eight women is affected by breast cancer during their lifetime and surgery is an essential element in the management pathway.<sup>21</sup> As the majority of breast cancer patients will require adjuvant treatment after surgery, swift recovery is essential in preventing delays. Such delays ultimately affect outcome and survival. Furthermore, NPWT may play a role in improving the cosmetic outcome by reducing the tension in the surgical wound, obliteration of the dead space and minimizing tissue injury by protecting the wound from contamination and infection.<sup>22</sup> Randomized controlled clinical trials that are currently under progress will show if the NPWT is able to provide women undergoing immediate breast reconstruction, better outcomes due to a faster healing process and superior aesthetic results when compared to the conventional post-operative wound dressings.<sup>23</sup>

The current evidence supports the notion that NPWT systems are beneficial in enhancing the healing of complicated breast wounds. However, larger studies exploring the effectiveness of this technique are required.

## ACKNOWLEDGMENT

We would like to thank Rihana Saad Abdalla from the BMAT STEM Academy School, in Harlow-England and Jakub Saad Abdalla from the Pemberley Academy Primary School in Harlow-England for their extra-ordinary work to prepare some of the included figures.

## REFERENCES

- [1] A. S. A. Al-Zawi, A. Lazarevska, M. M. Omer, E. Tan, A. Asaad, and S. Sathananthan, "Metastatic breast cancer to the cervix presenting with abnormal vaginal bleeding during chemotherapy: A case report and literature review," *Chirurgia*, vol. 113, pp. 564–570, 2018.
- [2] T. Banasiewicz, "Npwt sentenced to success," *Negative Pressure Wound Therapy*, vol. 1, pp. 1–4, 2014.
- [3] T. Awad and M. Butcher, "Handling the sequelae of breast cancer treatment: use of npwt to enhance patient independence," *Journal of wound care*, vol. 22, no. 3, pp. 162–166, 2013.
- [4] J. R. Burke, R. Morley, and M. Khanbhai, "Using portable negative pressure wound therapy devices in the home care setting," *Smart Homecare Technology and TeleHealth*, vol. 2, p. 129, 2014.
- [5] R. Vidya, "Negative pressure dressing audit. royal wolverhampton nhs trust." [Online]. Available: <http://picotrial.co.uk>.
- [6] T. Banasiewicz, A. Bobkiewicz, and M. Borejsza-Wysocki, "Portable vac therapy improve the results of the treatment of the pilonidal sinus—randomized prospective study," *Polish Journal of Surgery*, vol. 85, no. 7, pp. 371–376, 2013.
- [7] A. Bobkiewicz, A. Studniarek, M. Drews, and T. Banasiewicz, "Negative pressure wound therapy with instillation (npwti): Current status, recommendations and perspectives in the context of modern wound therapy," *Negative Pressure Wound Therapy Journal*, vol. 3, no. 1, 2016.
- [8] W. T. Stoeckel, L. David, E. A. Levine, A. E. Argenta, and N. D. Perrier, "Vacuum-assisted closure for the treatment of complex breast wounds," *The Breast*, vol. 15, no. 5, pp. 610–613, 2006.
- [9] R. Holt and J. Murphy, "Pico™ incision closure in oncological breast surgery: a case series," *British Journal of Hospital Medicine*, vol. 76, no. 4, pp. 217–223, 2015.
- [10] P. M. Ferrando, A. Ala, R. Bussone, L. Bergamasco, F. A. Perinetti, and F. Malan, "Closed incision negative pressure therapy in oncological breast surgery: comparison with standard care dressings," *Plastic and Reconstructive Surgery Global Open*, vol. 6, no. 6, 2018.
- [11] A. Gabriel, S. R. Sigalove, and G. P. Maxwell, "Initial experience using closed incision negative pressure therapy after immediate post-mastectomy breast reconstruction," *Plastic and Reconstructive Surgery Global Open*, vol. 4, no. 7, 2016.
- [12] D. Y. Kim, S.-J. Park, S.-I. Bang, G.-H. Mun, and J.-K. Pyon, "Does the use of incisional negative-pressure wound therapy prevent mastectomy flap necrosis in immediate expander-based breast reconstruction?" *Plastic and reconstructive surgery*, vol. 138, no. 3, pp. 558–566, 2016.
- [13] A. Gabriel, S. Sigalove, N. Sigalove, T. Storm-Dickerson, J. Rice, P. Maxwell, and L. Griffin, "The impact of closed incision negative pressure therapy on postoperative breast reconstruction outcomes," *Plastic and Reconstructive Surgery Global Open*, vol. 6, no. 8, 2018.
- [14] A. Angspatt, T. Laopiyasakul, P. Pungrasmi, and P. Suwajo, "The role of negative-pressure wound therapy in latissimus dorsi flap donor site seroma prevention: a cohort study," *Archives of plastic surgery*, vol. 44, no. 4, p. 308, 2017.
- [15] R. D. Galiano, D. Hudson, J. Shin, R. Van Der Hulst, V. Tanaydin, R. Djohan, F. Duteille, J. Cockwill, S. Megginson, and E. Huddleston, "Incisional negative pressure wound therapy for prevention of wound healing complications following reduction mammoplasty," *Plastic and Reconstructive Surgery Global Open*, vol. 6, no. 1, 2018.
- [16] A. Accurso, N. Rocco, G. Accardo, P. Reale, C. Salerno, E. Mattera, and F. D'Andrea, "Innovative management of implant exposure in adm/implant-based breast reconstruction with negative pressure wound therapy," *Aesthetic plastic surgery*, vol. 41, no. 1, pp. 36–39, 2017.
- [17] E. K. Kostaras, G. S. Tansarli, and M. E. Falagas, "Use of negative-pressure wound therapy in breast tissues: evaluation of the literature," *Surgical infections*, vol. 15, no. 6, pp. 679–685, 2014.
- [18] V. Strugala and R. Martin, "Meta-analysis of comparative trials evaluating a prophylactic single-use negative pressure wound therapy system for the prevention of surgical site complications," *Surgical infections*, vol. 18, no. 7, pp. 810–819, 2017.
- [19] P. Vikatmaa, V. Juutilainen, P. Kuukasjärvi, and A. Malmivaara, "Negative pressure wound therapy: a systematic review on effectiveness and safety," *European Journal of Vascular and Endovascular Surgery*, vol. 36, no. 4, pp. 438–448, 2008.
- [20] M. S. Timmers, S. Le Cessie, P. Banwell, and G. N. Jukema, "The effects of varying degrees of pressure delivered by negative-pressure wound therapy on skin perfusion," *Annals of plastic surgery*, vol. 55, no. 6, pp. 665–671, 2005.
- [21] A. S. A. Al-Zawi, M. Lange-Ratajczak, W. Chicken, S. Karamanakos, P. Idaewor, M. Elamass, E. Tan, and A. Asaad, "Pyloric metastases from primary breast cancer – a case report and literature review," *JMSCR*, vol. 5, no. 11, pp. 30 098–30 105, 2017.
- [22] J. Ogden, "Improving outcome in complex patients – breast surgery." [Online]. Available: <https://improving-outcomes-online.com/kom/breast-surgery>
- [23] T. Damsgaard, "Incisional negative pressure wound therapy (inpwt) in immediate breast reconstruction." [Online]. Available: <https://clinicaltrials.gov/ct2/show/NCT03069885>



# IMPROVING MEDICAL CARE

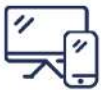by supporting the use on new technologies in medicine



clinical trials and observational studies



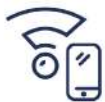medical registries



mobile and web applications



innovative medical devices



telemedical and patient-oriented outcomes using mobile technologies

## PROJECTS



Application designed for conducting a clinical trial in the field of pre- and postoperative nutrition. Medigent Foundation created in cooperation with Nutricia mobile application processing data in this area. The application is available on all platforms.

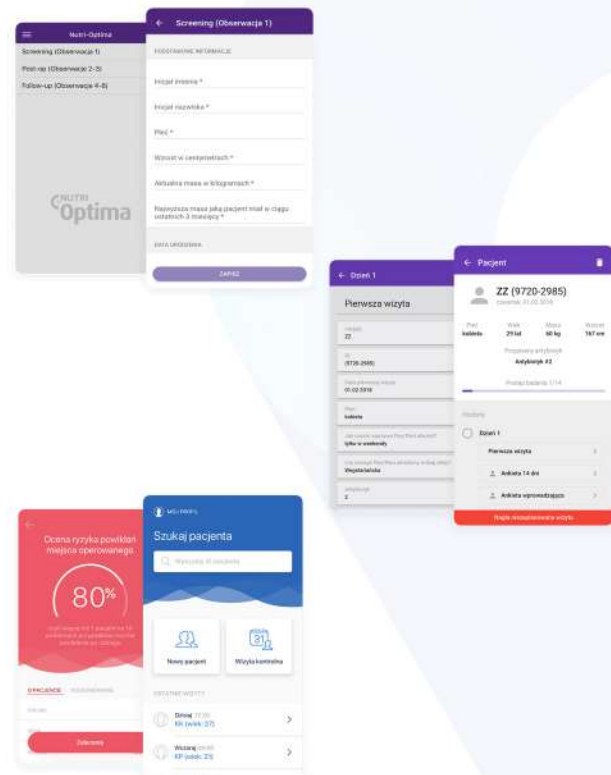


powered by Medigent

Application designed for conducting and evaluating a clinical trial on a group of patients testing new medical solutions. The application has been improved with a system which monitors daily quality of patient's life and data analysis.



Medical application for risk assessment of postoperative complications. The solution gives doctors a tool that supports their clinical decisions. Application enables to quickly and accurately estimate the real risk of postoperative complications of the patient. An additional advantage of the application is the ability to automatically generate printable reports, which significantly improves the work of doctors.

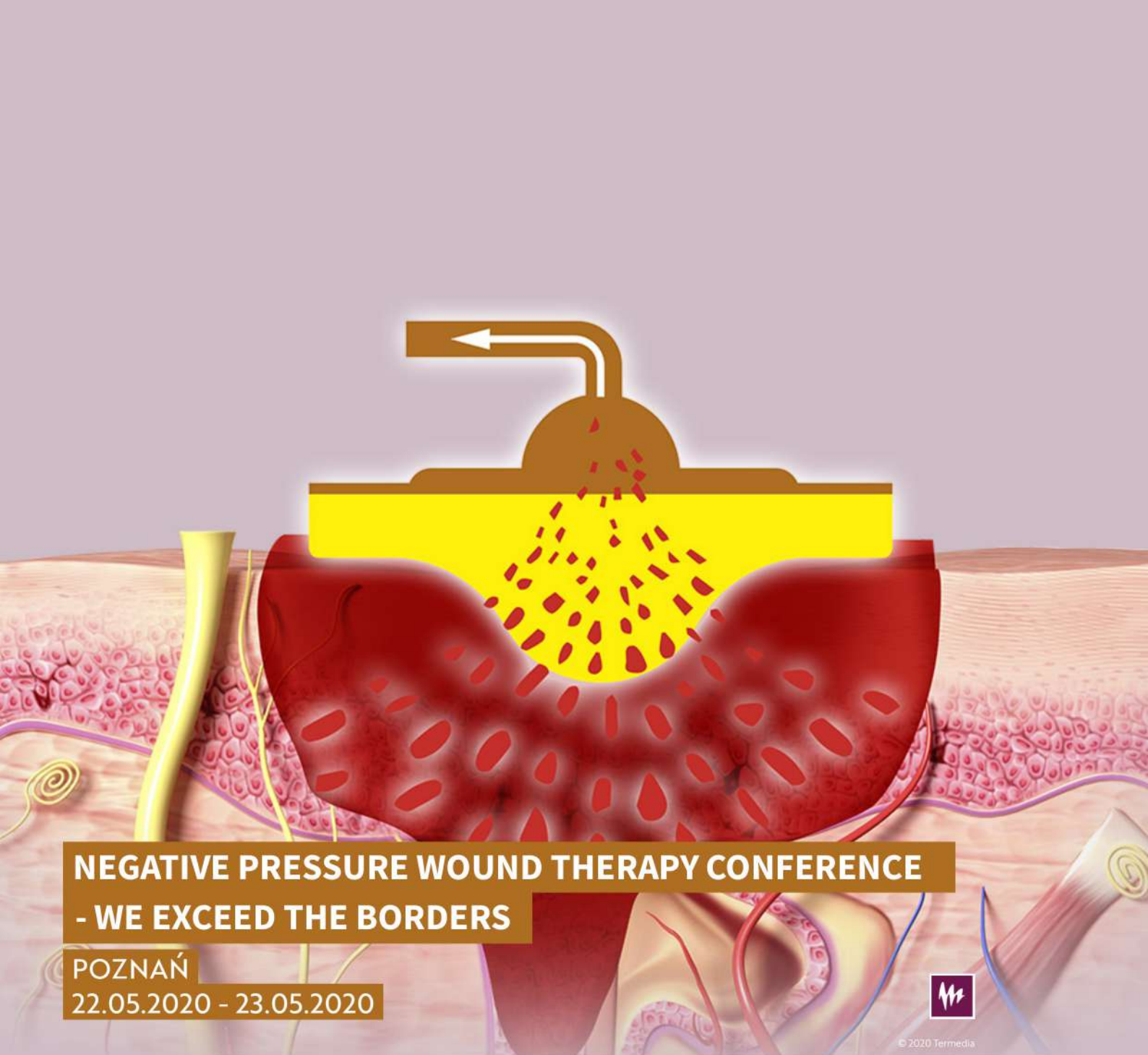

Foundation currently supports work on two IoT medical devices that will soon support home and hospital patient care.



## PARTNERS





**NEGATIVE PRESSURE WOUND THERAPY CONFERENCE  
- WE EXCEED THE BORDERS**

**POZNAŃ  
22.05.2020 - 23.05.2020**



© 2020 Termedia

<https://bit.ly/37IIJ5R>