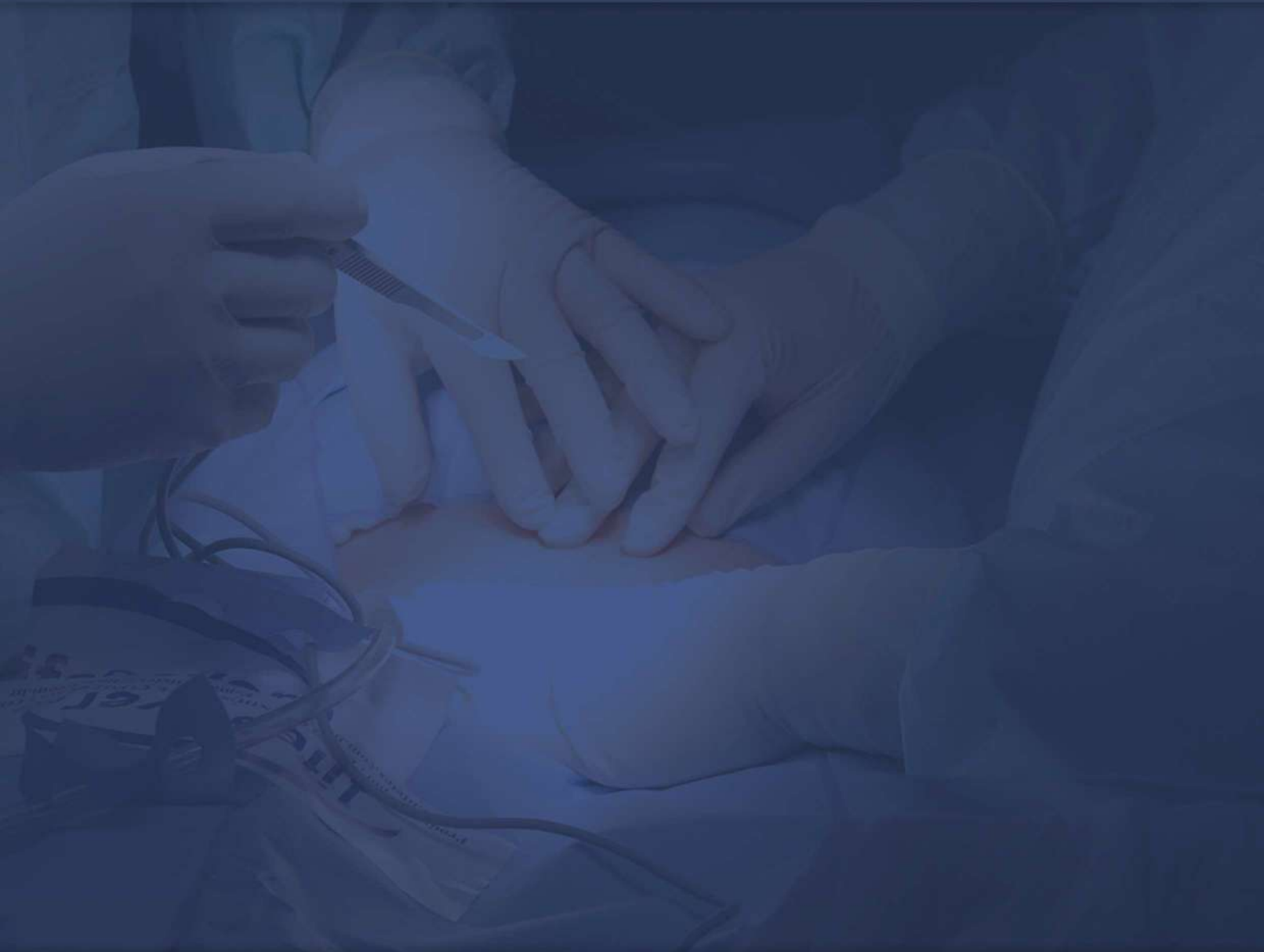

NEGATIVE PRESSURE WOUND THERAPY JOURNAL

VOLUME 6

| ISSUE 2

| JUNE 2019



JOURNAL EDITORIAL BOARD

Editor in Chief Prof. Tomasz Banasiewicz	Poznań, Poland	Dr. Mankowski Bartosz Prof. Marciniak Ryszard Prof. Niezgoda Jeffrey A. Prof. Malinger Stanisław Prof. Oszkini Grzegorz Prof. Pramod Kumar Prof. Georgi Popivanov, Prof. Runkel Norbert Prof. Salomone Di Saverio, Prof. Sopata Maciej Prof. Szejsza Jacek Prof. Toth Csaba Dr. Trueman Paul Dr. Trzeciak Piotr Prof. Siemionow Maria Prof. Stojcev Zoran Dr. Sukhbir Singh New Prof. Szczepkowski Marek Prof. Szentkereszty Zsolt Dr. Dominik Walczak Prof. Wallner Grzegorz Prof. Wild Thomasz Prof. Veverkova Lenka Prof. Angel Zorraquino Prof. Zhou Ye-ping Dr. Zieliński Maciej	Poznań, Poland Poznań, Poland West Allis, USA Poznań, Poland Poznań, Poland Saudi Arabia Sofia, Bulgaria Villingen-Schwenningen, Germany Bologna, Italy Poznań, Poland Poznań, Poland Debrecin, Ungarn Hull, UK Belchatow, Poland Cleveland, USA Ślupsk, Poland Delhi, India Warszawa, Poland Debrecin, Ungarn Łódź, Poland Lublin, Poland Hamburg, Germany Brno, Czech Republic Bilbao, Spain Beijing, China Poznań, Poland
Statistics Editor Prof. Elżbieta Kaczmarek Managing Editor Wojciech Francuzik Editorial Board Prof. Becker Rolf Dr. Bobkiewicz Adam Dr. Borejsza Wysocki Maciej Prof. Cirocchi Roberto Dr. Cybułka Bartosz Prof. Drews Michał Prof. Duteille Franck Prof. Dziki Adam Prof. Fraccalvieri Marco Prof. Heiney Jake P. Prof. Hudson Donald Prof. Hutan Martin Prof. Ichioka Shigeru Prof. Kościński Tomasz Dr. Krokowicz Łukasz Prof. Krokowicz Piotr Prof. Larichev B. Andrea Prof. Mike G. Laukoetter	Poznań, Poland Poznań, Poland Poznań, Poland Köln, Germany Poznań, Poland Poznań, Poland Perugia, Italy Gorzów Wielkopolski, Poland Poznań, Poland Nantes, France Łódź, Poland Torino, Italy Lambertville, USA Cape Town, South Africa Bratislava, Slovakia Saitama, Japan Poznań, Poland Poznań, Poland Poznań, Poland Jaroslav Russi Muenster, Germany		

PUBLISHER

The Medigent Foundation deals with the introduction of new technologies in medicine. Mobile applications that support doctors' decisions are of particular importance to us. To date, the Foundation has completed several projects with international partners creating new solutions in the field of medicine and new technologies. We would like to invite all interested parties to cooperate: innovators, doctors and new partners, to create new tools and solutions for medicine.

Medigent - A foundation in which doctors create solutions for doctors

SUBSCRIPTIONS

Negative Pressure Wound Therapy Journal is published quarterly by Medigent Foundation in Poland.

All content is publicly available free of charge on the www.npwtj.com webpage. Readers who would like to be notified of new issues may register using a form on www.npwtj.com.

COPYRIGHT

All works published in this journal are shared under Creative Commons 4.0 Attribution Licence unless specified otherwise.

Statements and opinions expressed in the articles and communications are those of the individual contributors and not the statements and opinion of the Publisher.

DISCLAIMER

We take no responsibility or liability for any damage or injury to persons or property arising out of the use of any materials, instructions, methods or ideas contained herein. We expressly disclaim any implied warranties of merchantability or fitness for a particular purpose.

CONTACT INFORMATION

Address:

Negative Pressure Wound Therapy Journal,
Clinic of General Surgery, Gastroenterologic
Oncology and Plastic Surgery,
Przybyszewskiego 49, 60355, Poznań

Telephone: +48 61-869-12-75

Fax: +48 61-869-16-84

Electronic mail: editor@npwtj.com

Web: www.npwtj.com

Publisher:

Medigent Foundation NIP: 779 245 69 65
ul. Grunwaldzka 66/2 Poznań, 60-311 Poland
www.medigent.org

TRADEMARKS

Trademarked names appearing in the pages of NPWTJ are property of their owners. The following list should not be considered complete: V.A.C. is a trademark of Kinetic Concepts, Inc.; Pico is a trademark of Smith & Nephew.

ACKNOWLEDGEMENTS

Cover: Joanna Francuzik

SUBMISSIONS

Editors of NPWTJ welcome all authors to submit their works for publication in the NPWTJ journal. We provide a thorough peer review and best recognition of your work. Send your work to our office by logging into our website: www.npwtj.com. Please use our online form to speed up the process.

TABLE OF CONTENTS

CASE REPORTS

SINGLE-USE NPWT DEVICE WITH TELEMEDICAL WOUND MONITORING IN THE TREATMENT OF ACNE INVERSA IN A PREGNANT PATIENT – CASE REPORT
Kinga Zastawna, Alicja Żalejko-Strychalska, Tomasz Banasiewicz 4

EDITORIAL

INSTILLATION-TIME (iTIME) AS A RATIONALE AMENDMENT FOR TIME CONCEPTION. IS THERE ENOUGH EVIDENCE FOR THE ECENCY OF NEGATIVE PRESSURE WOUND THERAPY WITH INSTILLATION (iNPWT) TO ANNOUNCE A BREAKTHROUGH IDEA FOR WOUND TREATMENT?
A. Bobkiewicz, A. Studniarek, L. Krokowicz, M. Drews, T. Banasiewicz 7

Single-use NPWT device with telemedical wound monitoring in the treatment of acne inversa in a pregnant patient – case report

Kinga Zastawna, Alicja Żalejko-Strychalska, Tomasz Banasiewicz

CASE REPORT

Abstract— Acne inversa (AI) is a chronic inflammatory skin disease significantly impacting the patient's quality of life. Management guidelines for acne inversa during pregnancy do not exist. We decided to use a single-use negative pressure wound therapy (PICO, Smith & Nephew) while managing a pregnant patient with AI. Negative pressure wound therapy (NPWT) seemed to improve the patient's condition, managing the exudation, reducing edema, and improving local regeneration, as well as epithelialization. The method was also absolutely safe for the fetus and feasible to conduct in the outpatient department - what was of utmost importance for the patient. The telemedical monitoring of wound healing using mobile technologies seems to be gaining importance for patients and medical practitioners. In the described case, we used the iWound (Polmedi, Poland) application in an outpatient setting.

Keywords—acne inversa, NPWT, telemedicine, iWound App, pregnancy, hidradenitis suppurativa

INTRODUCTION

ACNE inversa (*hidradenitis suppurativa*) is a chronic inflammatory skin disease, with a significant impact on quality of life.¹ The disorder is generally difficult to treat and in pregnant women.^{2, 3} There are limited publications and guidelines delineating treatment of acne inversa during pregnancy. We present a case report of a 30-year-old, pregnant woman, with moderate acne inversa treated with NPWT. We decided to use single-use negative pressure wound therapy (PICO), regarding the patient's pregnancy. The local treatment of inflammation and reduction of septic condition was the main target of therapy. NPWT is an effective and safe method in this type of wounds.^{4, 5}

The main aim of this article is to emphasize the importance of vacuum therapy together with the constant telemedical monitoring of the wound healing, what we were able to achieve using iWound App (Polmedi, Poland).

Manuscript received 25.05.2019; revised 20.07.2019. This work did not receive any financial support. TB is the CEO of Polmedi Sp. z o.o.

Author affiliations: Department of General and Endocrine Surgery and Gastroenterological Oncology Department, Poznan University of Medical Sciences, Poznan, Poland, (KZ, AŻS, TB)

*Correspondence to: Kinga Zastawna: kinga.zastawna@gmail.com

PATIENT INFORMATION AND CLINICAL FINDINGS

We describe the case of a 30 years old female patient, who presented with typical symptoms of acne inversa in the area of the perineum, both groins, and inner thighs. At the moment of admission to the hospital, the patient was 16 weeks pregnant. She was diagnosed with acne inversa ten years before the described incident when the symptoms developed in the axillary area, and she underwent surgery with a satisfactory effect. The patient described the present statement as "much worse and unbearable." The symptoms included the presence of painful nodules, abscesses and sinus tracts forming fistulas with a tendency to tissue fibrosis. However, the disease seemed to have no remarkable effect on the pregnancy the patient reported that first symptoms occurred coincidentally with the pregnancy diagnosis. At that stage, she started developing anxiety and symptoms of depression. Due to potential adverse reactions to general anesthesia, we excluded broad surgical excision. We also had limited pharmacotherapy options due to the pregnancy. Additionally, the patient presented no other pathologies and concomitant diseases, no similar cases in the family medical history. The patient did not smoke nor use alcohol.

THERAPEUTIC INTERVENTION

The patient was admitted to the dermatological ward and received conservative treatment. A team of physicians consisting of a dermatologist, gynecologist, anesthesiologist, and a surgeon were regularly consulting the patient and decided to perform surgical drainage of the inguinal abscesses under the short-term anesthesia. The surgical approach was limited to drainage of the lesions rather than performing the typically recommended radical procedure to avoid a possible compromise to the patient's pregnancy. In patients with AI skin lesions less often cause sepsis or lymphadenopathy, but we were obliged to treat her due to an elevated risk of miscarriage.

The localization of the wounds and lesions was problematic for the regular NPWT dressing as we did not want to limit the patient's movements, so we decided to introduce the NPWT using PICO (Smith & Nephew) soon after surgery. The small PICO system was easily changeable and removable

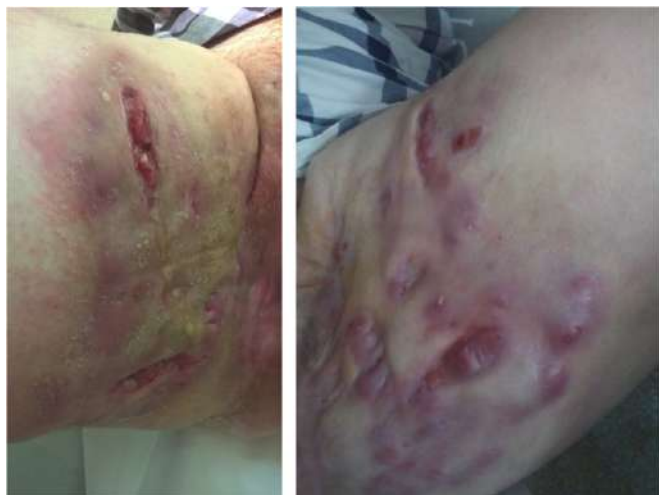

Figure 1. Both treated inguinal areas on the day of the hospital discharge.

by the patient whenever leakage necessary. We continued the NPWT for two weeks after the surgery, with the dressing change every two days in the beginning and every three days later (5 changes in total) and the concomitant intravenous antibiotic therapy. Perioperative antibiotic therapy corresponded to bacteriological tests, performed from lesional skin swabs, taking the potential risk for embryotoxicity in concern (erythromycin 600 mg i.v. three times a day and cefotaxime 2 g i.v. twice daily for ten days).

After hospitalizing the patient for 22 days, we reached the point when the patient could be discharged from the hospital and instructed about the following home treatment, which included topical application of ichthyol and starch suspension twice daily. To keep the constant monitoring of the patient's wound, we proposed using a smartphone application, what was potentially beneficial due to minimizing the need for outpatient clinic visits. The patient enthusiastically agreed to create an account in the test version of the iWound App (Polmedi, Poland), which offered an easy and fast communication in case of any complications. There was no requirement to keep the patient hospitalized neither in dermatology or surgery department (due to the high risk of infection in both wards) nor in gynecology or obstetrics department (no pregnancy complications during the entire period of pregnancy). We instructed the patient on how to use the iWound App and how often she should contact the doctor. She sent photographs by the application and information about pain and color and amount of discharge every three days right after she left the hospital, and once a week 14 days later. She was also instructed not to hesitate to contact the doctor if any pregnancy-related symptoms would occur. However, she was strongly advised to stay under the obstetrician's care according to his recommendations. After the surgical treatment supported by NPWT, we observed no more severe activity of acne inversa. The patient was monitored as an outpatient until she gave birth in the 38th week. The patient did not require another hospitalization, and the pregnancy was terminated on time by cesarean section.

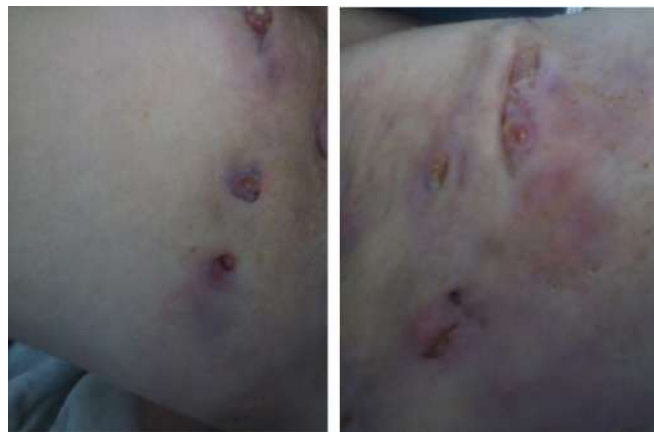

Figure 2. Photographs taken by the patient at home and sent by the iWound App 6 weeks after she was discharged from the hospital.

DISCUSSION

Although pregnancy is a physiological state, it brings much anxiety when the patient needs hospitalization for unrelated disorders. Being aware of this statement combined with an infectious disease, which unquestionably is acne inversa, we saw the need for a reliable ambulatory monitoring of the patient. The treatment was aimed to minimize the negative impact of AI rather than only introduce radical surgical therapy.

NPWT seemed to be in this case well-suited for improving the healing potential, managing the exudation, reducing edema, improving local regeneration, as well as epithelialization. The method was also, what was crucial for patients, absolutely safe, and feasible to use in the outpatient department. The other benefit was the reduction of the number of wound dressing changes and reducing odor, which posed discomfort for the patient. Single-use NPWT, as in our case, is the easiest way to use NPWT in wound treatment after surgery. The method is simple to use for the patient, and the device operates with just one button. One potential difficulty is the location of the wound dressing, which can introduce problems to keep the vacuum dressing sealed. The experience of the medical staff and the use of stoma paste as a sealant is most suited for the proper functioning of the system, especially in a complicated localization. In our case, we did not observe any significant leaks; no extra visits to the outpatient clinic or emergency wound dressing removal was necessary.

With a holistic view of the patient situation, we tried to address the difficulties that could occur regarding frequent visits, spending time in public transportation or the risk of nosocomial infections in the outpatient clinic. The telemedical application seemed to be well-suited and used by patients and medical staff instruments for monitoring of wound healing with increasing frequency.^{6,7} In the described case the iWound application was used — created by Polmedi, Poland, in collaboration with Chair and Department of General and Endocrine Surgery and Gastroenterological Oncology Department, Poznań University of Medical Sciences, Poznań, Poland. In our and patient's opinion, iWound is very easy to

use and allows for monitoring and permanent contact with the patient. It is personalized and stores all information together with the photographs of the wound, which is essential due to two aspects. First, it gives the physician the possibility of monitoring patient's healing, second, provides both — the patient and the physician with the visual progress of wound-healing, what is vital from the psychological point of view.⁸

CONCLUSION

The ambulatory therapy of the wound, mainly including negative pressure wound therapy, require the regular control of wound healing due to early detection of potential problem and monitoring of the quality of healing. In discharged patients treated with NPWT, it seems to be very important to control the effectiveness of the therapy, early detection of some technical problems (leak, device's alarms), control of type and volume of exudation, as well as to decide when the vacuum dressing should be changed. The smartphone application allows patients to control better and monitor the therapy as well as improve safety. Medical staff can benefit from it by optimizing the frequency of outpatient visits. It can reduce the number of non-necessary visits, as well as allow intervening in case of any acute complications rapidly. In our opinion, ambulatory NPWT treatment can be very effective when combined with telemedical systems for wound healing monitoring; the next step could be direct monitoring

of vacuum devices by telemedical monitoring systems or mobile applications.

REFERENCES

- [1] N. Scheinfeld, "Hidradenitis suppurativa: a practical review of possible medical treatments based on over 350 hidradenitis patients," *Dermatology online journal*, vol. 19, no. 4, 2013.
- [2] C. Kromann, I. Deckers, S. Esmann, J. Boer, E. Prens, and G. Jemec, "Risk factors, clinical course and long-term prognosis in hidradenitis suppurativa: a cross-sectional study," *British Journal of Dermatology*, vol. 171, no. 4, pp. 819–824, 2014.
- [3] P. Perng, J. Zampella, and G. Okoye, "Considering the impact of pregnancy on the natural history of hidradenitis suppurativa," *British Journal of Dermatology*, vol. 178, no. 1, pp. e13–e14, 2018.
- [4] E. Chen and H. I. Friedman, "Management of regional hidradenitis suppurativa with vacuum-assisted closure and split thickness skin grafts," *Annals of plastic surgery*, vol. 67, no. 4, pp. 397–401, 2011.
- [5] T. Banasiewicz, A. Bobkiewicz, and M. Borejsza-Wysocki, "Portable vac therapy improve the results of the treatment of the pilonidal sinus—randomized prospective study," *Polish Journal of Surgery*, vol. 85, no. 7, pp. 371–376, 2013.
- [6] P. C. Sanger, A. Hartzler, S. M. Han, C. A. Armstrong, M. R. Stewart, R. J. Lordon, W. B. Lober, and H. L. Evans, "Patient perspectives on post-discharge surgical site infections: towards a patient-centered mobile health solution," *PLoS One*, vol. 9, no. 12, p. e114016, 2014.
- [7] J. S. Abelson, M. Symer, A. Peters, M. Charlson, and H. Yeo, "Mobile health apps and recovery after surgery: What are patients willing to do?" *The American Journal of Surgery*, vol. 214, no. 4, pp. 616–622, 2017.
- [8] J. Ye, Y. Zuo, T. Xie, M. Wu, P. Ni, Y. Kang, X. Yu, X. Sun, Y. Huang, and S. Lu, "A telemedicine wound care model using 4g with smart phones or smart glasses: A pilot study," *Medicine*, vol. 95, no. 31, 2016.

Instillation-TIME (iTIME) as a rationale amendment for TIME conception. Is there enough evidence for the efficiency of negative pressure wound therapy with instillation (iNPWT) to announce a breakthrough idea for wound treatment?

A. Bobkiewicz, A. Studniarek, L. Krokowicz, M. Drews, T. Banasiewicz

EDITORIAL

Abstract— An increased number of patients developing difficult-to-heal wounds results in billions spending for chronic wound care management. Introduction of TIME conception has been a breakthrough idea for wound healing based on phase-adapted wound therapy that interacts and influence each other and included: T — tissue management, I — infection control, M — moisture balance, E — edge of the wound. Negative pressure wound therapy (NPWT) revolutionized the management of wound healing. Moreover, recently NPWT with installation (iNPWT) has gained the popularity of optimizing wound healing.

In the context of acceleration of wound healing, iNPWT meets the criteria of the TIME conception. All individual components of TIME strategy are found in iNPWT providing “all in one” conception. Such management is easy to apply, monitor and it is well-tolerated by patients. Based on the current studies, iNPWT is found to be an important alternative for other methods of wound healing. It is believed that iNPWT will evolve and gain popularity as an innovative treatment for TIME conception.

Keywords—TIME, negative pressure wound therapy, installation, wound healing

ALTHOUGH, the general principles of appropriate management of wound bed preparation had been known even earlier, it was in 2000 when Falanga et al. published the report of the phase-adapted wound healing using the acronym TIME.¹ This conception is composed of four individual elements that interact and influence each other:

- 1) tissue management,
- 2) infection control,
- 3) moisture balance and
- 4) wound edge.

Manuscript received 25.05.2019; revised 04.07.2019. This work did not receive any financial support. Authors declare no conflict of interest.

Author affiliations: Department of General, Endocrinological Surgery and Gastroenterological Oncology Poznan University of Medical Sciences Przybyszewskiego 49, 60-355 Poznan, Poland, (AB, AS, LK, MD, TB)

*Correspondence to: Adam Bobkiewicz: bobofon007@gmail.com

The key TIME philosophy seems to promote significantly improved wound healing. Another breakthrough strategy that increased the rate of wound healing is NPWT. Since its introduction, NPWT has been considered a reasonably successful method for modern management of wound healing.² In 1998, Fleischmann et al. combined the standard NPWT with a localized application of drugs.³ In 2003, the first commercialized system of iNPWT was introduced to general practice. It combines the benefits of standard NPWT with incorporated, controlled and periodic installation of topical solution to the bed wound.

In the context of acceleration of wound healing, iNPWT meets the criteria of the TIME conception. It was proven that iNPWT facilitates the removal of wound exudate, cellular debris and inflammatory molecules that may impair the process of appropriate wound healing (representing Tissue management). The use of topical solutions facilitates the wound decontamination resulting in bacterial biofilm reduction (representing Infection control).^{4, 5} Composition of dressings with specially designed reticulated open-cell foam (ROCF) allows for appropriate adherence and distribution of instilled fluid within the wound. Moreover, application of instilled fluid keeps the moisture balance within the wound bed (representing Moisture balance).^{6, 7} Negative pressure influences the re-epithelialization from the wound edges due to wound bed granulation, and remodeling of fibroblasts, extracellular matrix, as well as increased growth factor production.^{8, 9} Using iNPWT, acceleration of wound filling and collagen deposition was observed within the wound bed, in both — experimental models as well as in clinical scenarios.^{10, 11}

All above-mentioned mechanisms of action studied in vitro and experimental studies were confirmed in clinical scenarios and in various types of wounds. Recently, a preliminary international consensus guideline was published to summarize the current state of the art regarding iNPWT.¹² Moreover, further comprehensive reviews were published to

define the use, settings and instilled solutions for optimal utility of iNPWT indicating the increased value of iNPWT in the field of wound healing.^{13–15} Currently, iNPWT is used as a method of choice in open fracture, pressure ulcer and non-healing, complex postoperative wounds with a high rate of wound closure.^{11, 16, 17} In the recent multi-center prospective observational study, iNPWT was used for implant-associated infection following a knee or hip implant placement confirmed with the eradication of the wound infection in 75% of patients.¹⁸ Similar results were achieved by others indicating the low rate of reinfection and high rate of wound closure using a skin graft, flaps or secondary closure.^{19, 20}

Based on our experience, iNPWT possesses the principles promoting wound healing and decisively fulfill the conception of TIME management. All individual components of TIME strategy are found in iNPWT providing “all in one” conception. Such management is easy to apply, monitor and it is well-tolerated by patients. Based on the current studies, iNPWT is found to be an important alternative for other methods of wound healing with an increased number of publications confirming its high efficiency. It is believed that iNPWT will evolve and gain popularity as an innovative treatment for TIME conception.

REFERENCES

- [1] V. FALANGA, “Classifications for wound bed preparation and stimulation of chronic wounds,” *Wound repair and regeneration*, vol. 8, no. 5, pp. 347–352, 2000.
- [2] M. J. Morykwas, L. C. Argenta, E. I. Shelton-Brown, and W. McGuirt, “Vacuum-assisted closure: a new method for wound control and treatment: animal studies and basic foundation,” *Annals of plastic surgery*, vol. 38, no. 6, pp. 553–562, 1997.
- [3] W. Fleischmann, M. Russ, A. Westhauser, and M. Stampehl, “Vacuum sealing as carrier system for controlled local drug administration in wound infection,” *Der Unfallchirurg*, vol. 101, no. 8, pp. 649–654, 1998.
- [4] A. Gabriel, J. Shores, C. Heinrich, W. Baqai, S. Kalina, N. Sogioka, and S. Gupta, “Negative pressure wound therapy with instillation: a pilot study describing a new method for treating infected wounds,” *International wound journal*, vol. 5, no. 3, pp. 399–413, 2008.
- [5] P. L. Phillips, Q. Yang, and G. S. Schultz, “The effect of negative pressure wound therapy with periodic instillation using antimicrobial solutions on pseudomonas aeruginosa biofilm on porcine skin explants,” *International wound journal*, vol. 10, no. s1, pp. 48–55, 2013.
- [6] C. Lessing, P. Slack, K. Hong, D. Kilpadi, and A. McNulty, “Negative pressure wound therapy with controlled saline instillation (npwti): dressing properties and granulation response in vivo,” *Wounds*, vol. 23, no. 10, p. 309, 2011.
- [7] C. Mouës, F. Heule, and S. Hovius, “A review of topical negative pressure therapy in wound healing: sufficient evidence?” *The American Journal of Surgery*, vol. 201, no. 4, pp. 544–556, 2011.
- [8] S. S. Scherer, G. Pietramaggiori, J. C. Mathews, M. J. Prsa, S. Huang, and D. P. Orgill, “The mechanism of action of the vacuum-assisted closure device,” *Plastic and reconstructive surgery*, vol. 122, no. 3, pp. 786–797, 2008.
- [9] A. Gabriel, J. Shores, C. Heinrich, W. Baqai, S. Kalina, N. Sogioka, and S. Gupta, “Negative pressure wound therapy with instillation: a pilot study describing a new method for treating infected wounds,” *International wound journal*, vol. 5, no. 3, pp. 399–413, 2008.
- [10] B. K. Leung, L. A. LaBarbera, C. A. Carroll, D. Allen, and A. K. McNulty, “The effects of normal saline instillation in conjunction with negative pressure wound therapy on wound healing in a porcine model,” *Wounds*, vol. 22, no. 7, pp. 179–87, 2010.
- [11] D. Brinkert, M. Ali, M. Naud, N. Maire, C. Trial, and L. Teot, “Negative pressure wound therapy with saline instillation: 131 patient case series,” *International wound journal*, vol. 10, no. s1, pp. 56–60, 2013.
- [12] P. J. Kim, C. E. Attinger, J. S. Steinberg, K. K. Evans, B. Lehner, C. Willy, L. Lavery, T. Wolvos, D. Orgill, W. Ennis *et al.*, “Negative-pressure wound therapy with instillation: international consensus guidelines,” *Plastic and reconstructive surgery*, vol. 132, no. 6, pp. 1569–1579, 2013.
- [13] P. J. Kim, C. E. Attinger, O. Olawoye, B. D. Crist, A. Gabriel, R. D. Galiano, S. Gupta, J. Lantis II, L. Lavery, B. A. Lipsky *et al.*, “Negative pressure wound therapy with instillation: review of evidence and recommendations,” *Wounds*, vol. 27, no. 12, pp. S2–S19, 2015.
- [14] A. Bobkiewicz, A. Studniarek, M. Drews, and T. Banasiewicz, “Negative pressure wound therapy with instillation (npwti): Current status, recommendations and perspectives in the context of modern wound therapy,” *Negative Pressure Wound Therapy Journal*, vol. 3, no. 1, 2016.
- [15] P. Kim, C. Attinger, J. Steinberg, and K. Evans, “Negative pressure wound therapy with instillation: past, present, and future,” *Surgical technology international*, vol. 26, pp. 51–56, 2015.
- [16] M. Tom Wolvos, “The use of negative pressure wound therapy with an automated, volumetric fluid administration: an advancement in wound care,” *Wounds*, vol. 25, no. 3, pp. 75–83, 2013.
- [17] W. Schreiner, O. Oster, P. Stapel, and H. Sirbu, “Vac instill® therapy—new option in septic thoracic surgery,” *Zentralblatt für Chirurgie*, vol. 138, no. 1, pp. 117–120, 2013.
- [18] B. Lehner, S. Weiss, A. Suda, D. Witte *et al.*, “Application of vac instill therapy in case of periprosthetic infection in hip arthroplasty,” *Infection*, vol. 37, no. Suppl 1, pp. 13–17, 2009.
- [19] G. Koster, “Management of early periprosthetic infections in the knee using the vacuum-instillation therapy,” *Infection*, vol. 37, no. Suppl 1, pp. 18–20, 2009.
- [20] M. Schintler, E.-C. Prandl, G. Kreuzwirt, M. Grohmann, S. Spendel, E. Scharnagl *et al.*, “The impact of vac instill in severe soft tissue infections and necrotizing fasciitis,” *Infection*, vol. 37, no. Suppl 1, pp. 31–2, 2009.

IMPROVING MEDICAL CARE

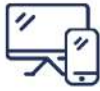by supporting the use on new technologies in medicine



clinical trials and observational studies



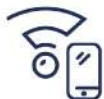medical registries



mobile and web applications



innovative medical devices



telemedical and patient-oriented outcomes using mobile technologies



PROJECTS

Application designed for conducting a clinical trial in the field of pre-and postoperative nutrition. Medigent Foundation created in cooperation with Nutricia mobile application processing data in this area. The application is available on all platforms.

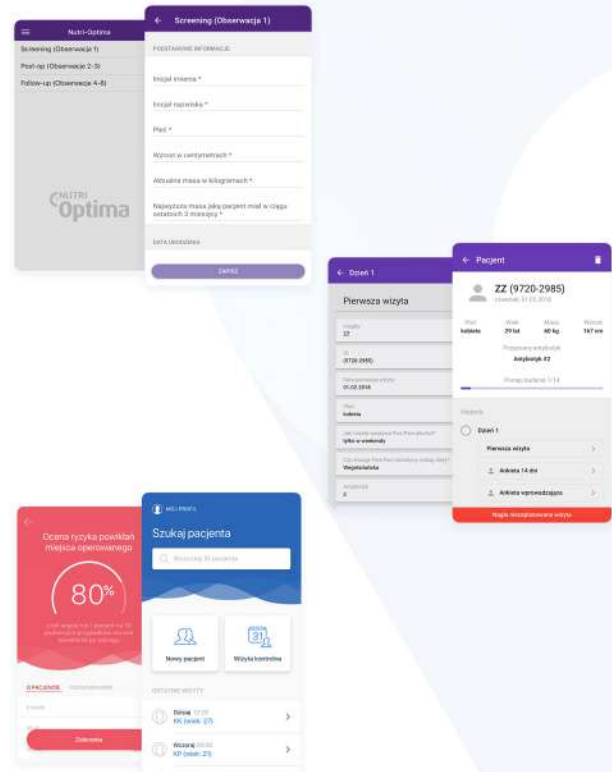
ECOLON

powered by Medigent

Application designed for conducting and evaluating a clinical trial on a group of patients testing new medical solutions. The application has been improved with a system which monitors daily quality of patient's life and data analysis.



Medical application for risk assessment of postoperative complications. The solution gives doctors a tool that supports their clinical decisions. Application enables to quickly and accurately estimate the real risk of postoperative complications of the patient. An additional advantage of the application is the ability to automatically generate printable reports, which significantly improves the work of doctors.



Foundation currently supports work on two IoT medical devices that will soon support home and hospital patient care.



PARTNERS

